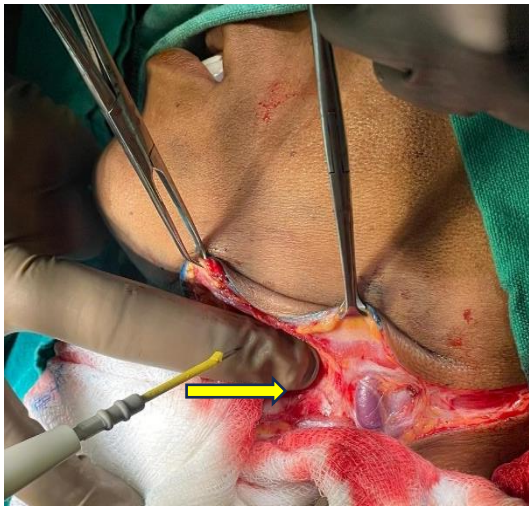
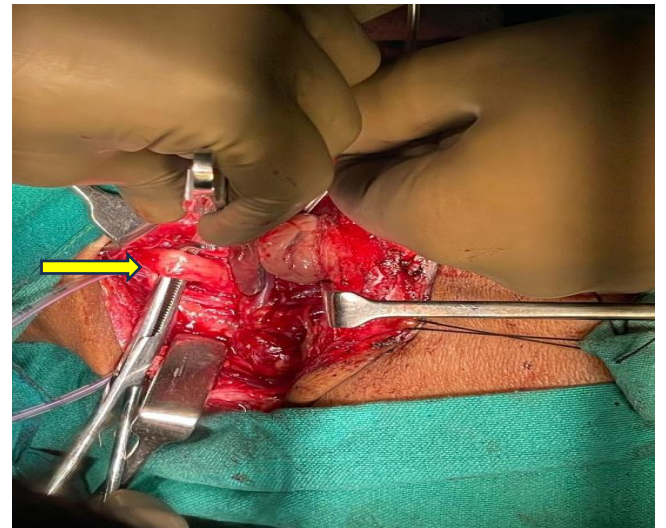


A RARE CASE OF PARAGANGLIOMA IN LEFT SIDE OF NECK



ARROW SHOWING TUMOUR



ARROW SHOWING FEEDING VESSEL

Kavita Wagh , 40/F ,
c/o Pain and difficulty in swallowing along with swelling on left side since 1 year.

O/E: Local examination revealed 4*2 cm swelling involving anterior pillar tonsillar fossa and posterior pillar on left.

CT Neck: Well defined mass lesion in Left parapharyngeal space, displacing carotid vessels measuring 44*22*41mm.

FNAC: Paraganglioma

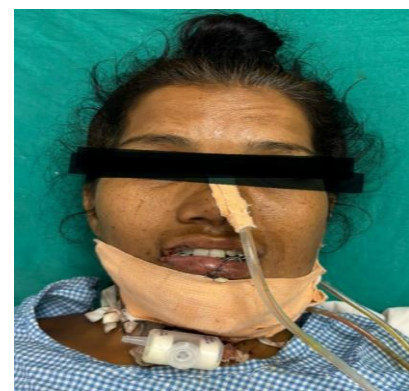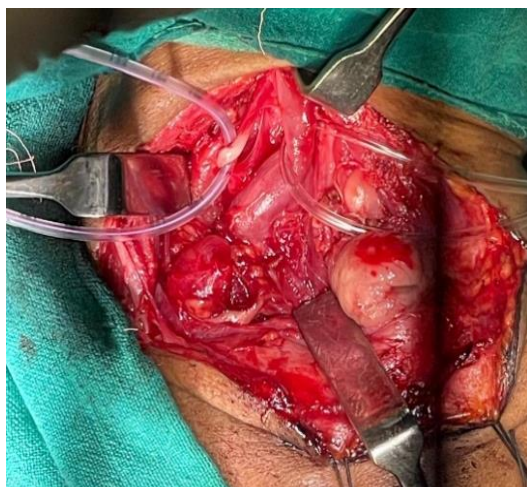MRI Face+ Neck: Well defined soft tissue mass lesion in left carotid space appearing isotense on T1WI and hypotense on T2WI with free flow voids within associated with splaying of internal and external carotid arteries indents the pharyngeal mucosal space.

Surgery Done: Transcervical and Transoral Approach with Mandibular Swing with excision of Left Parapharyngeal space tumor with Tracheostomy.

Summary: A well-orchestrated team work led by Dr. Pooja Nagare, Prof & Hod ENT, which led to successful excision of carotid body tumour within the fork of common carotid vessel and extending to the parapharyngeal space (**possibly the first case of this institute**).

The procedure was carried out with precision and with exemplary perseverance resulting into excision of highly vascular mass, displaying competency, commitment and leadership of Dr. Pooja. Intraoperative period was though very stormy, but patient was resuscitated well .

Kudos, to the team ENT led by Prof & Hod for accomplishing such a rare feat within the Rural set up of ours.



POST OP PHOTOGRAPH

TEAM:

Dr. Pooja Nagare (Chief surgeon)
Professor and HOD
Dept of ENT Head and Neck Surgery

Anaesthetist: Dr.Amol & team

Collaborating Surgeon:

Maj. Gen. Dr. S K Jha VSM
CVTS Surgeon
Professor and HOD
Department of General Surgery

Assistant

Dr. Tahir Khan
Dr. Rishikesh Pawar
Dr. Maitreyee
Dept of ENT Head and Neck Surgery