

Quiz Section (Quiz No. 4, Vol. 01) NEURORADIOLOGY QUIZ

Gandage S.G., Aironi V.D., Chandurkar Milind, Moradiya Mahesh, Sharma Gagan

Case History

A seventy year old woman presented with weakness of left upper and lower limbs with involuntary movements of left upper and lower limb since two months. She was investigated and found to have diabetes mellitus. Her CT head scan revealed following findings as seen in Figures 1, 2 and 3. What is possible diagnosis?

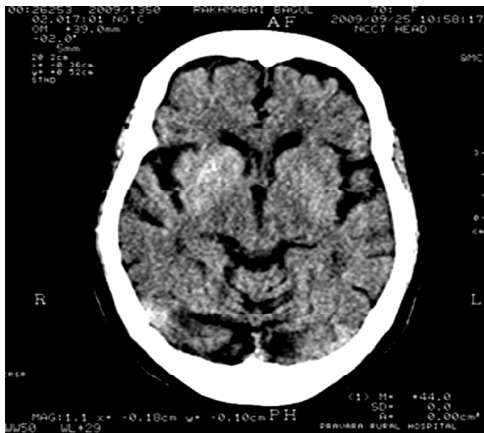


Figure 1: Plain CT scan of Brain

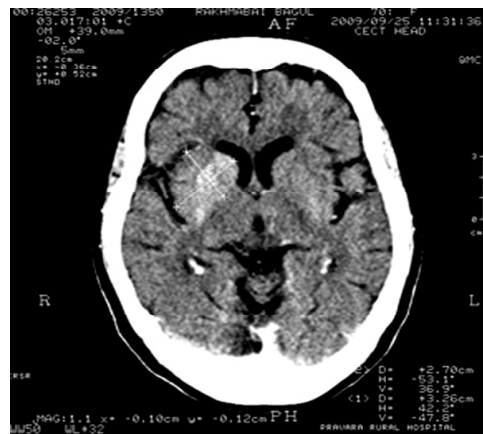

Figure 2: Postcontrast CT scan of Brain

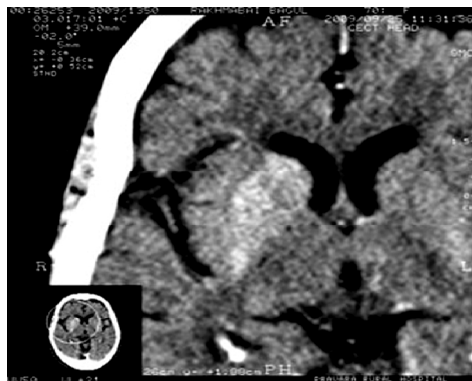

Figure 3: Magnified CT image of right basal ganglia