

Haemangiopericytoma of Mandible in a 9 year old patient- A rare case report

Niyati Malik*, Seemit Shah**, Anuj Dadhich***

Abstract

Hemangiopericytoma (HPC) is an uncommon mesenchymal tumour, which was first described by Stout and Murray in 1942. Only 15% of haemangiopericytomas occur in the head and neck region and it is extremely rare in the paediatric age group. The present report describes a case of haemangiopericytoma of the mandible occurring in a 9 year old patient.

Introduction

Haemangiopericytoma arises from the pericytes of Zimmerman, which form capillaries and regulate luminal size^[1,2]. Although this tumour can occur anywhere in the body within the vascular tissue, it is common in lower extremities, pelvis and retroperitoneum while only 15-20% occur in head and neck region^[2]. The tumour has no gender predilection and is common in fourth to sixth decade of life and 82% are Caucasians^[3,4]. HPC is extremely rare in paediatric age group with the incidence <10%^[4]. The etiology of the tumour is unclear though various theories have been proposed like trauma that stimulates the proliferation of pericytes, long-term use of corticosteroids and vascular hypertension, but unproven^[5]. There is some ambiguity regarding the management of these lesions, and the available literature is also less. We report a case of HPC of the mandible in a 9 year-old patient. The purpose of this report is to describe the clinical presentation, diagnosis and management of this lesion with a focus on previous literature.

Case Report

A 9-year-old male patient presented to the department of oral and maxillofacial surgery with a chief complaint of painless swelling and intraoral mass in the lower jaw on the right side since 2 to 3 months, which was gradually increasing in size. A detailed case history had been taken that denied any significant medical, family, or personal history. On extra-oral examination, a firm, nontender, non fluctuant swelling, measuring about 3 cm × 2 cm in size was seen at the right body, angle and ramus of mandible region. The swelling was, noncompressible, and the skin overlying was normal and free from the underlying swelling. There was no regional or distant lymphadenopathy. Intra oral examination revealed an abnormal soft tissue overgrowth in the right retromolar region which was irregular in shape and approximately 3x3 cm in size. The growth did not show any evidence of bleeding. The patient already had 2 biopsy reports with him (outsourced) one of which suggested that it was a keratocystic odontogenic tumour and the second suggested that it was a soft tissue malignancy. The patient was then subjected to radiological scans. Orthopantomogram revealed a radiolucent lesion in the right ramus of mandible region. Computed tomography (CT) showed severe bony erosion in the right side ramus region. CBCT of the mandible showed marked erosion of the right ramus of mandible

*3rd yr PG Student, **Prof. & Head, ** Reader & PG Guide
Dept. of Oral & Maxillofacial Surgery, Rural Dental College, Loni

Corresponding Author:

Niyati Malik*
Dept. of Oral & Maxillofacial Surgery, Rural Dental College, Loni
E-mail ID: dr.niyatimalik@gmail.com, Contact number: 9920718232

which was extending upto the neck of condyle, sigmoid notch and the coronoid process. An incisional biopsy was done and sent for immunohistochemistry that showed spindle shaped cells of a solid tumour with fibrous tissue and numerous small vessel formations marking the diagnosis of Haemangiopericytoma. The patient was operated under GA by segmental mandibulectomy of the ramus region sparing the head of the condyle (for secondary reconstructive surgery) . The approach taken was by an extraoral lip split incision extending to the mastoid process. After careful dissection and preservation of the marginal mandibular nerve, segmental mandibulectomy of the ramus was carried out from distal to the permanent first molar tooth to the condyle (sparing the head of the condyle). The intraoral lesion was also excised. Primary reconstruction was done with a recon plate and the patient has been kept on follow up. Secondary reconstruction with a free fibula graft will be planned after a minimum follow up of 5 years.

The excised specimen was sent for histopathological examination, which confirmed the preoperative diagnosis of Haemangiopericytoma. Mitotic figures and other dysplastic changes were absent on histopathological examination. The patient was under regular review and during followup after 1-year, mild facial asymmetry was noticed but there was no evidence of recurrence.

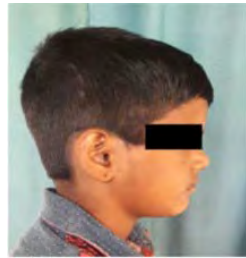

FIGURE 1

FIGURE 2

FIGURES 1 & 2 showing pre-op images of the patient with swelling on the right side of the mandible (angle & ramus region)

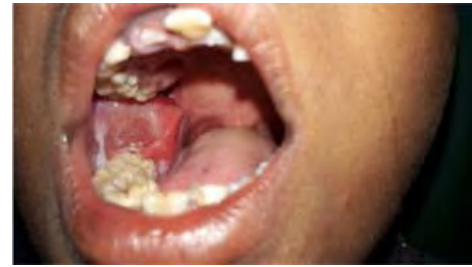

FIGURE 3 showing the intraoral growth

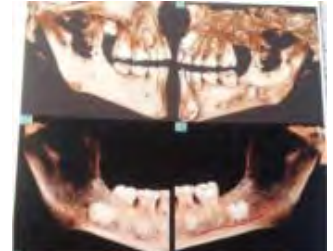
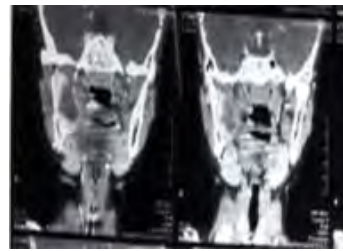


FIGURE 4

FIGURE 5

FIGURES 4 & 5 showing the CT & CBCT that show the erosion of the ramus of mandible extending upto the sigmoid notch, condyle and coronoid process

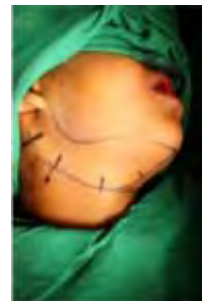

FIGURE 6 showing initial marking of incision which was later on extended for lip-split

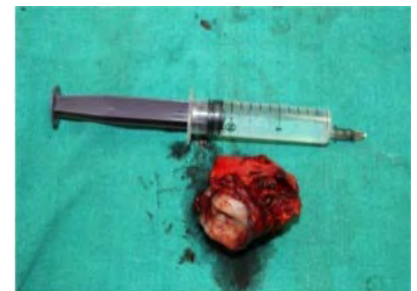

FIGURE 7 showing resected part of ramus of mandible with intraoral growth

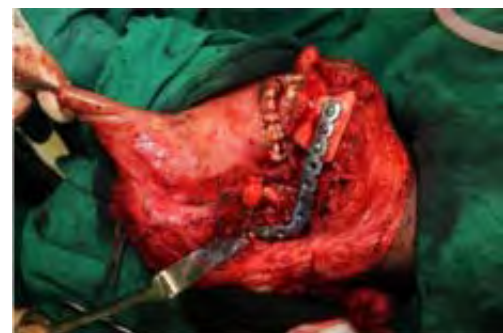

FIGURE 9 showing the application of a Recon plate for primary reconstruction

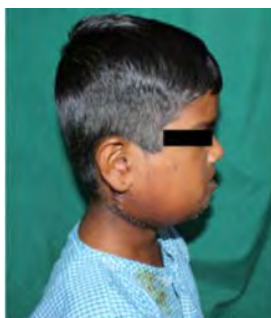

FIGURE 10 showing immediate post-op image of the patient on the 5th day

Discussion

Hemangiopericytomas account for >1% of all vascular tumors^[6]. Though uncommon in head and neck region (10-15%), tumors involving tongue, floor of the mouth, cheek, lips, nose, paranasal sinuses, maxilla and mandible, pharynx, parotid and orbital region have been reported by Bastakis and Rice^[7]. In the present report, it was seen in the ramus of mandible. As it arises from capillary pericytes, it can occur in any part of the body containing capillaries. HPCs can be both benign and malignant, and the distinction is often difficult. HPCs occurring in infants younger than 1-year behave differently from those occurring in children older than 1-year and adults^[4]. Clinical presentation of nonspecific pain is a late symptom associated with an enlarging mass, which was not reported by our patient^[8].

Hemangiopericytomas have a tendency to metastasize early or late through vascular and lymphatic route^[8]. Local recurrences are also common. The rate of metastasis of a malignant variety is reported to be >75% (including both local and distant)^[9]. Distant metastasis however, follow one or more local recurrences and a rare case of metastatic HPC to lung after 20 years of its initial occurrence in mandible was reported by Ravenel and Goodman^[9], which indicates the emphasis on long-term follow-up. Conventional radiographs are rarely diagnostic of HPC. CT and MRI are the usual techniques for evaluating these tumours. Angiography reveals their vascular nature^[3,9].

There is some ambiguity regarding the management of these lesions and only a few reports regarding its clinical management have been published since HPC is very rare in children. However, surgery is considered the main stay of treatment though radiotherapy and chemotherapy have a role to play in malignant cases. Most common treatment

for HPC is wide surgical excision. Some authors have suggested presurgical embolization to reduce the risk of intra operative bleeding. Initially, the tumor was thought to be radioresistant^[8], but the recent literature supports radiotherapy as an adjuvant with doses between 60 and 70 Gy in case of incomplete excision of tumor, local recurrences and high grade malignancy^[3,10]. In our case, as histopathological examination revealed a benign variant and complete surgical removal was done ensuring the safe margins (>1 cm), radiotherapy was not given and the patient did not show any evidence of recurrence at a 1 year follow up.

The patient will be kept on a long term follow up (minimum 5 years) and then planned for a secondary reconstructive surgery if there is no recurrence.

Conclusion

Wide surgical excision is the most accepted management of HPC. Early diagnosis reduces the postsurgical morbidity and improves the prognosis. Radiotherapy can be considered as an adjunct to surgery to prevent recurrence in cases when the variant is of a malignant type. Since, local recurrences are very common and distant metastasis has been reported to occur even many years after primary occurrence, long term follow-up, both clinically and radiologically is mandatory.

References

1. Bhutia O, Choudhury AR. Hemangiopericytoma of mandible. *J Oral Maxillofac Pathol* 2008;12:26-8.
2. Yamanishi T, Nishio J, Inoue M, Yasui M, Toribe Y, Takeuchi M, et al. A case of congenital maxillary hemangiopericytoma: A case report. *J Oral Maxillofac Surg* 2007;65:549-52.
3. Thiele OC, Freier K, Flechtenmacher C, Rohde S, Hofele C, Mühling J, et al. Haemangiopericytoma of the mandible. *J Craniomaxillofac Surg* 2010;38:597-600.
4. Sinha A, Rawson K, Singh G. A rare case of hemangiopericytoma in the maxilla of a 4 year old child. *J Indian Acad Oral Med Radiol* 2010;22:S64-6.
5. Krishnan M, Kumar KS, Sowmiya T. Hemangiopericytoma - The need for a protocol-based treatment plan. *Indian J Dent Res* 2011;22:497.

6. Anand R, Gupta S. Hemangiopericytoma of maxilla in a pediatric patient: A case report. *J Dent Child (Chic)* 2010;77:180-2.
7. Batsakis JG, Rice DH. The pathology of head and neck tumors: vasoformative tumors, part 9B. *Head Neck Surg* 1981; 4 : 326-39.
8. Tatum RC, Skinner HG, Adrian J. Hemangiopericytoma of the parotid: report of a rare case with literature review. *Quintessence International* 1986; 17:399-403.
9. Ravenel JG, Goodman PC. Late pulmonary metastasis from hemangiopericytoma of mandible unusual findings on CT and MR imaging. *Am J Roentgenol* 2001;177:244-5.
10. Bianchi B, Poli T, Bertolini F, Sesenna E. Malignant hemangiopericytoma of the infratemporal fossa: Report of a case. *J Oral Maxillofac Surg* 2002;60:309-12.