

Conservative management of diseased roots: A case report

Saurabh Pawar*, Basawaraj Biradar**, Aparna Palekar***, S. Sai Kalyan**, Renuka Nadar*, Dhanashree Thorat*

Abstract

Modern advancements in dentistry has provided many means by which dentition can be maintained in function for lifetime. The decision to retain multi-rooted teeth is based on multiple aspects such as caries, furcation involvement, periodontal involvement, remaining tooth structure, post and core builds ups and endodontic treatment. Many studies have been carried out which proved that maintenance of teeth with diseased root can be done in the dental arch successfully with a proper treatment planning and multidisciplinary approach. These case reports encompass simple procedures of hemisection and root resection, its importance in preserving normal tissue and its function.

Keywords: Root resection, Hemisection, Furcation

Introduction

Success in clinical dentistry requires thorough understanding of the anatomical and biologic nature of the tooth, its components as well as its supporting tissues. Any pathologic changes in the tooth such as caries, or supporting structures, increases the chances of developing a root pathology.

Recent advances in the field of dentistry has given us various treatment modalities to save the tooth with root(s) which have developed pathologies and maintain a functional dentition.^[1] Loss of tooth is an undesirable event, which creates further issues, such as tooth drifting, loss of arch length (space loss), loss of masticatory function and bone loss. Such problems further requires preventive and maintenance measures.^[2]

Management of periodontally involved teeth or carious root has always been a challenge. Earlier treatment option was limited to extraction and replacement of the tooth with implant or a fixed or removable prosthesis. Now, retaining such tooth required endodontic, periodontal and prosthetic assessment.^[1,3]

Hemisection and root resection are the conservative approaches for preserving a tooth. Hemisection is the removal of compromised root structure along with its associated crown portion

through deliberate excision,^[4] whereas root resection is surgical removal of one of the root along with the adherent soft tissue leaving the crown of the tooth intact supported by remaining root(s).^[5] Blomlof *et al.*,^[6] found out the survival rate of the root resected endodontically treated molars to be 68-70% over a 10-year period. This article describes successful cases of hemisection and root resection followed by successful healing and functioning.

Case Report

Case 1 (Hemisection)

A 45-year old male reported to the department of Conservative Dentistry and Endodontics with the complaint of pain and food lodgement in the lower left back region of the jaw, which was endodontically treated previously. Clinical examination revealed that the tooth was sensitive to percussion and revealed a 10 mm deep periodontal pocket around mesial root.

On radiographic examination, severe angular bone loss was evident surrounding the mesial roots leaving furcation intact. (Figure. 1) The bone surrounding the distal root was intact with slight marginal bone loss. Re-treatment procedure was initiated,

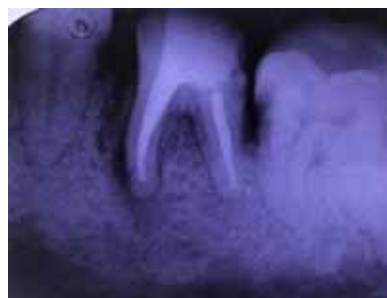

Figure 1 : Pre-operative radiograph

*Post-Graduate student, **Reader, ***Prof and Head

Corresponding author :

Dr. Saurabh Pawar,

Post-graduate student

Department of Conservative Dentistry & Endodontics

Rural Dental College, Pravara Medical Trust, LONI,

Taluka: Rahata, Dist: Ahemadnagar, Maharashtra – 413736

E-mail: saurabhpawar2516@gmail.com

Phone: 9673830593

gutta percha was retrieved and biomechanical preparation was done using rotary instrumentation. Intracanal medication of calcium hydroxide was placed for two weeks and obturation was performed, after thorough irrigation, with continuous wave of compaction technique. Post obturation restoration was done using light cure composite.

Under local anaesthesia, a full thickness flap was reflected from lower left first premolar to second molar. After flap reflection the bony defect was evidently visible. (Figure. 2) With the help of radiograph, a vertical cut was made in the crown towards bifurcation area. After ensuring the cut is complete, mesial part of the tooth was extracted using periosteal elevator and extraction forceps. Complete debridement of the socket was done, all the granulation tissue was removed and socket was irrigated with betadine and saline. It was made sure no sharp tooth margins was bony spicules were left behind. (Figure. 3)

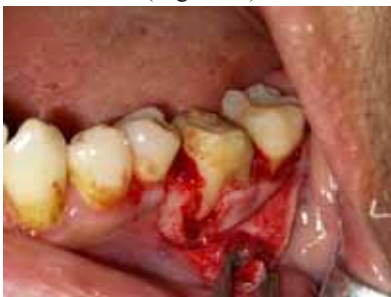

Figure 2 : Evident bone loss seen after flap reflection

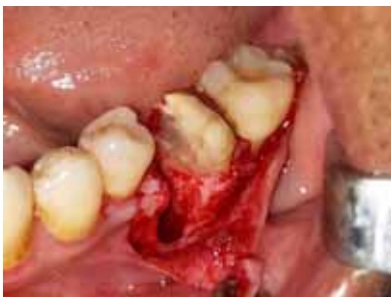

Figure 3 : Removal of mesial fragment

The extraction site was irrigated and flap was repositioned and sutured with 3-0 silk. The distal part of the tooth was reduced to minimise the occlusal forces on it. Patient was recalled 1 week for suture removal and further recalls were performed at one, three and six months to check for satisfactory healing. (Figure. 4) After healing, fixed bridge involving retained distal half and adjacent premolar was planned.

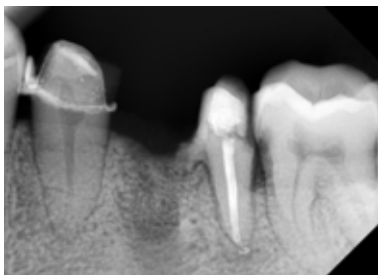


Figure 4 : Post-operative radiograph after 6 months

Case 2 (Root resection)

A 38 year old male reported to the department of Conservative Dentistry and Endodontics with the complaint of food lodgement and pain in the maxillary right molar region. On examination, the tooth was tender to percussion with deep pocket on distal aspect of the tooth. Radiographic examination revealed caries on distal wall the tooth extending till coronal third of distobuccal root, exposing the respective canal. Also, slight bone loss was present in the same region. (Figure. 5)

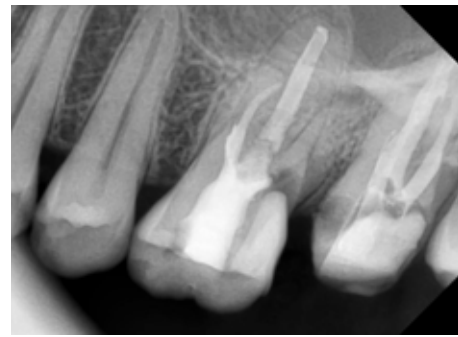


Figure 5 : Pre-operative radiograph. Cervical caries seen extending in to the pulp space of disto-buccal root

It was decided to treat the tooth endodontically and then root resection was planned. Biomechanical preparation was done using rotary instrumentation and obturation was performed with continuous wave of compaction technique. Post obturation restoration was done using light cure composite.

Under local anaesthesia, a full thickness flap was reflected from upper right second premolar to second molar. Troughing around the disto-buccal root was done and a slit was made from furcation area so as to cut the root off the tooth. (Figure. 6) After ensuring the root is free from the tooth, a purchase point was made and root piece was elevated and removed using periosteal elevator. (Figure. 7) The cut surface of tooth was smoothed and retrograde GIC (GC fuji IX) was placed. Polishing of the surface was done followed by curettage of the socket. Flap repositioning was done and sutured with 3-0 silk. Patient was recalled 1 week for suture removal and further recalls were performed at one, three and six months to check for satisfactory healing. (Figure. 8)

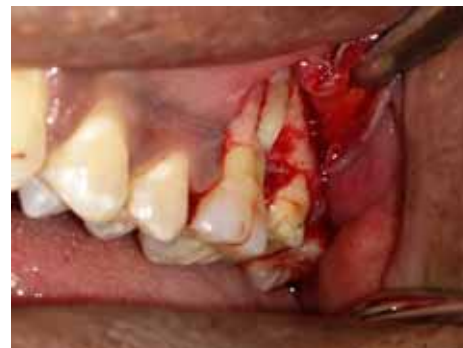

Figure 6 : After flap reflection

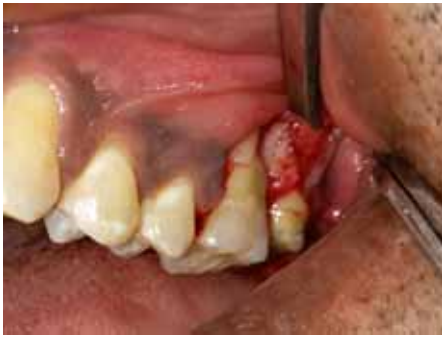

Figure 7 : Removal of Disto-buccal root fragment

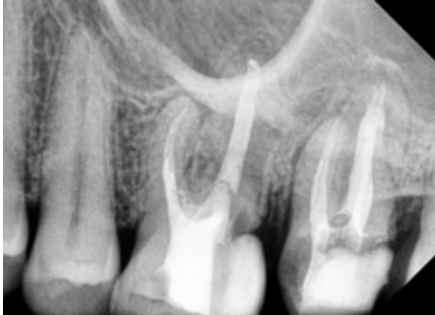

Figure 8 : Post-operative radiograph

Discussion

The anatomical intricacies of furcated roots such as concavities and convexities, cervical enamel projections (CEPs), shallow width of furcation area affects the removal of microbial niches from the root surfaces. Sometimes the basic self-performed oral hygiene procedures or even the professional prophylactic treatment fail to debride, which affects the long term prognosis of multi-rooted teeth.^[7] Bower in his study showed that 81% of all the furcation entrances have diameter of upto 1mm and 58% has less than 0.75mm, which badly affects instrumentation in these areas.^[8] Debridement of furcation canal is also a major contributing factor. Hemisection and root resection are the conservative treatment options where extraction of the involved root(s), which is preceded by the complete root canal treatment of the remaining tooth and followed by proper restoration and prosthetic rehabilitation, maintaining the remaining tooth portion in function and occlusion.^[9]

Hemisection has been successfully done to retain mandibular molars, which is either periodontally involved or vertically fractured instead of completely extracting a whole tooth. Conservation of what is present is far better than meticulous removal of the structure. Hemisection is indicated in teeth with vertical or angular bone loss, furcation destruction, and dehiscence exposing root surface, vertical fracture, and endodontic failures. Advantage of this procedure is that physiologic tooth mobility is maintained by this procedure, which acts as a more apt abutment for the fixed partial dentures than an osseo-integrated counterpart.^[10] Saad *et al* have shown greater success and long term results (upto 10 years) with hemi-sectioned teeth.^[3,9,11] high success rate depends on factors like small occlusal table, under

contouring of embrasure spaces, crown margin encompassing the furcation, sufficient bone height and proper endodontic treatment.^[12] Also its cost effectiveness is another advantage over implants. In this case hemisection was advised due to endodontic failure.

Root resection is another option to extend the function of a molar with root caries or persistent periodontal problems or endodontic failures. Patient in this case came with constant pain and food lodgement complaint, which indicted cervical root caries, confirmed by radiograph. Also a bony defect was present. Long term prognosis of such tooth depends on the quality of recontouring of the remaining tooth structure after root resection and final restoration, which will further reflect the periodontal status.^[13,14]

Treatment choice depends on the various factors such as amount of bone loss, furcation involvement, and cost effectiveness. Root amputation and hemisection have been preferred in case where implant is not a feasible option.^[15] Fugazzotto *et al*^[16] investigated resected molars and single tooth implants and resulted in similar success rates of 96% after 11-13 years of function. Whereas residual bone support for more than 50% of roots was found to be good predictor for its survival.^[16]

Conclusion

Root resection and hemisection should be considered as a valid and predictive treatment option and alternative to implant therapy which should be followed by careful prosthetic rehabilitation. With recent refinements in endodontics, periodontics and restorative dentistry, root separation and resection has been recognised as a conservative and dependable dental treatment options so as the treated teeth will endure its functional demands.

References

1. Jain A, Bahuguna R, Agarwal V. Hemisection as an alternative treatment for resorbed multirooted tooth-a case report. *Asian J Oral Health Allied Sci.* 2011;1:45.
2. Behl AB. Hemisection of a multirooted tooth-A case report. *Open Access Sci Rep.* 2012;1:1-3.
3. Radke U, Kubde R, Paldiwal A. Hemisection: a window of hope for freezing tooth. *Case Rep Dent.* 2012 Aug 14;2012:390874.
4. Bühler H. Survival rates of hemisected teeth: an attempt to compare them with survival rates of alloplastic implants. *Int J Periodontics Restorative Dent.* 1994 Dec;14(6):536-43.
5. Glossary of Endodontic Terms 2016 [Internet]. [cited 2018 Feb 11]. Available from: <http://www.nxtbook.com/nxtbooks/aae/endodonticglossary2016/index.php#/1>
6. Blomlöf L, Jansson L, Appelgren R, Ehnevid H, Lindskog S. Prognosis and mortality of root-resected molars. *Int J Periodontics Restorative Dent.* 1997 Apr;17(2):190-201.

7. Ntolou P, Prevezanos I, Karoussis IK. Prognosis of Furcation Involved Teeth: Cost-Effectiveness over Implant Placement. *Dental Health: Current Research* [Internet]. 2016 Dec 5 [cited 2018 Feb 12];2016. Available from: https://www.scitechnol.com/peer-review/prognosis-of-furcation-involved-teeth-costeffectiveness-over-implant-placement-kh0d.php?article_id=5374
8. Bower RC. Furcation Morphology Relative to Periodontal Treatment: Furcation Root Surface Anatomy. *J Periodontol*. 1979 Jul 1;50(7):366–74.
9. Saad MN, Moreno J, Crawford C. Hemisection as an alternative treatment for decayed multirooted terminal abutment: a case report. *J Can Dent Assoc*. 2009 Jun;75(5):387–90.
10. Kost WJ, Stakiw JE. Root amputation and hemisection. *J Can Dent Assoc*. 1991 Jan;57(1):42–5.
11. Shah S, Modi B, Desai K, Duseja S. Hemisection-A conservative approach for a periodontally compromised tooth-A Case Report. *Journal of Advanced Oral Research* [Internet]. 2012; Available from: <http://www.joaor.org/hemisection-a-conservative-approach-for-a-periodontally-compromised-tooth-a-case-report-article.html>
12. Rapoport RH, Deep P. Traumatic hemisection and restoration of a maxillary first premolar: a case report. *Gen Dent* [Internet]. 2003; Available from: <http://europepmc.org/abstract/med/15055612>
13. Langer B, Stein SD, Wagenberg B. An Evaluation of Root Resections: A Ten-Year Study. *J Periodontol*. 1981 Dec 1;52(12):719–22.
14. KLAVAN, B. Clinical observation following root amputation in maxillary molar teeth. *J Periodontol*. 1975;46:105.
15. Desanctis M, Murphy KG. The role of resective periodontal surgery in the treatment of furcation defects. *Periodontol 2000* [Internet]. 2000; Available from: <http://onlinelibrary.wiley.com/doi/10.1034/j.1600-0757.2000.2220110.x/full>
16. Fugazzotto PA. A comparison of the success of root resected molars and molar position implants in function in a private practice: results of up to 15-plus years. *J Periodontol*. 2001 Aug;72(8):1113–23.

