

Case Report

Generalized oral pyogenic granuloma: Infrequent case report

¹Shaila Veerappa Kothiwale, ²Vishakha Keshav Padhye

¹MDS, Ph. D., Professor, Department of Periodontics, KAHER'S KLE Vishawanath Katti Institute of Dental Sciences, Belagavi, Karnataka, India

²BDS, Post-Graduate student, Department of Periodontics, KAHER'S KLE Vishawanath Katti Institute of Dental Sciences, Belagavi, Karnataka, India

Corresponding address : Shaila V. Kothiwale, Department of Periodontics, KAHER'S KLE Vishawanath Katti Institute of Dental Sciences, Belagavi, Karnataka, India, shailakothiwale2000@yahoo.co.in



Creative Commons Attribution
4.0 International License

CC BY 4.0

ABSTRACT

Pyogenic granuloma is a type of inflammatory reactive hyperplasia that mostly presents as a localized or solitary lesion. The present case is rare entity of generalized pyogenic granuloma. A 21-year-old male patient presented with generalized gingival enlargement to the Out Patient Department with recurrence of gingival enlargement without any contributory medical history, drug history and specific etiology. As per histopathological report of tissue biopsy of all three quadrant, enlargement was diagnosed as “Generalized Gingival Pyogenic Granuloma.”

The periodontal therapy included scaling and root planning with oral hygiene instructions followed by gingivectomy using electrocautery and combined gingivectomy and flap therapy in second quadrant. Since the pyogenic granuloma had high rate of recurrence, the patient was placed on the maintenance therapy.

Keywords – Pyogenic granuloma, Gingival enlargement, Reactive hyperplasia

INTRODUCTION:

Gingival enlargement is defined as an overgrowth or increase in size of the gingiva.^[1,3] The soft tissue enlargements are a group of reactive hyperplasias that develop in response to a recurring, chronic tissue injury which stimulates an excessive tissue repair response.^[2] According to Glickman, gingival enlargement can be classified as inflammatory, drug induced, associated with systemic diseases (leukemia, neoplastic enlargements), conditioned enlargements (puberty or pregnancy) and non-specific enlargements like “pyogenic granuloma.”^[3]

First case of pyogenic granuloma (PG) in English literature was described by Hullihen in 1844.⁵ It was then described in 1897 by, Poncet and Dor, who named this lesion “otyomycosis hominis”. However, in 1904 that Hartzell first ever introduced the term pyogenic granuloma.^[3]

The term pyogenic granuloma is a misnomer since the condition is not associated with pus nor does it represent a granuloma histologically, In reality, it is a lobular subtype of capillary hemangioma due to which the lesions frequently show spontaneous bleeding.^[3]

PG predominantly occurs on marginal gingiva (75%) with 15% of the tumors on the alveolar part. It is commonly observed in the

maxillary arch. The common sites of the lesion are lips, tongue and buccal mucosa. The size of the lesion varies from a few millimeters to centimeters and is generally bright red in color due to its high vascularity and bleeds spontaneously. As the lesion matures, it may appear pinkish and more collagenous due to a decrease in vascularity over the time.^[1]

It is observed that oral pyogenic granuloma comprised about 1.85% of all oral pathoses² and in an analysis of 244 cases of gingival lesions in south Indian population, found that oral pyogenic granuloma is most frequent lesion, accounting for 52.71% cases of 75.5% non-neoplastic lesions.^[4]

PG is a non specific conditioned gingival enlargement, mostly a localized exaggerated reactive hyperplasia of connective tissue of the oral cavity or skin in response to local factors and chronic irritation. But PG presenting as a generalized gingival enlargement is very rare and uncommon.^[5]

CASE REPORT:

A 21 year old male reported to the Department of Periodontology, KLE Vishwanath Katti Institute of Dental Sciences, Belagavi, Karnataka, India, with a chief complaint of swollen gums for the last 5 months. He reported that he noticed swollen gums since 5 months, which were painless with soft and edematous consistency and gradually increased in size to attain its present size (Figure 1a). He was unable to brush his teeth due to the increase in the size of the gums, had spontaneous bleeding.

Patient experienced a similar problem 17 months ago for which he was treated. This treatment rendered comfort to him for mastication, esthetics and for maintenance of the oral hygiene. Medical history was non contributory.

Extra-oral examination was normal. Intraoral examination revealed presence of gingival hyperplasia with the facial and buccal aspects of

the maxillary and mandibular teeth covering three-quarters or more of the crown structure. The degree of enlargement was Grade III in mandibular anteriors while it was Grade II in 1st, 2nd and 3rd quadrant (Figure 1a-c). On clinical examination with probing, generalized 5 to 7 mm pseudo pockets were detected. Attachment loss of 2 to 3 mm was observed in relation to the maxillary left premolars and molars. These lesions were asymptomatic. Patient's oral hygiene maintenance was compromised as the patient found it difficult to brush his teeth because of the enlarged gingiva and bleeding on brushing. This led to the deterioration of his oral hygiene.

INVESTIGATIONS:

Hemogram blood counts were normal. Orthopantomogram showed generalized mild horizontal bone loss.

HISTOPATHOLOGIC FEATURES:

For histopathologic examination, excisional biopsy was performed in the maxillary posterior and mandibular anterior regions and sent to the Department of General Pathology, KLE's Jawaharlal Nehru Medical College, Belagavi, Karnataka. The Hematoxylin-Eosin-stained sections were examined using a light microscope. Microscopically, active vessels characterized by a rich profusion of anastomosing vascular channels with areas of neovascularization admixed with inflammatory cells in edematous background stroma were seen. The dilated endothelial-lined vascular spaces showed presence of erythrocytes within them while some of the erythrocytes were found extravasated in focal areas of stroma. (Figure 3a) In the stromal cells, stromal fibroblasts were observed plump with mitotic activity. (Figure 3b, 4) Chronic and acute inflammatory cells were seen admixed with the scattered inflammatory infiltrate. There was ulceration and blunting of rete ridges seen in places in the overlying stratified squamous epithelium. (Figure 4) Neutrophil predominance was observed under

these areas of ulceration. These are classical features of pyogenic granuloma that helped established the diagnosis.

DISCUSSION:

In the present case, the patient had generalized gingival enlargement which was absent in the 4th quadrant. He had no complaints of bleeding gums but observed bleeding from his gums on brushing his teeth and had a history of gradual increase in the enlargement with no specific history contributing to etiology.

Any irritant applied to a living tissue may act either as a stimulus or as a destructive agent or both.^[4] It is postulated that habitual tooth brushing may also be considered as a significant cause of microtrauma and irritation to the gingiva leading to pyogenic granuloma formation. It has also been stated that pyogenic granuloma represents an exuberant connective tissue proliferation to a known stimulus or injury like calculus or foreign material within the gingival crevice.^[4]

Generalized pyogenic granuloma can be considered as a neovascular response to an angiogenic stimulus.^[1] there is excessive local production of tumor angiogenic factor as a consequence of a tissue lesion due to trauma^[1] and other cytokines particularly bFGF-a heparin binding angiogenic protein, has been found to be highly mitogenic for capillary endothelial cells and to induce angiogenesis.^[4]

According to the literature, very few cases of generalized pyogenic granulomas have been reported till date in literature, and the cases which have been reported mostly describe the generalized lesions of the skin and gastrointestinal tract, making it a rare entity. In the present case, the patient presented with generalized gingival enlargement with no specific contributory systemic involvement.

Proper understanding of the etiology and the underlying pathologic changes in pyogenic granuloma determines the treatment. Surgical

excision of pyogenic granuloma is the treatment of choice which also includes removal of the base of the lesion along with its extension down to the periosteum, and proper scaling, root planing and curettage of involved and adjacent teeth.^[3]

Considering the generalized nature of the granuloma in the present case, the following treatment was planned to eliminate local factors, supra and sub gingival scaling was performed in the first appointment and the patient was prescribed 2% betadine gargle with proper oral hygiene instructions. The patient was followed up for another 2 weeks during which root planing followed by curettage was performed and the patient was encouraged to maintain his oral hygiene. In recall visits, no reduction in the size of the lesion was observed. Therefore, surgical excision was planned and the lesion was excised under aseptic conditions. Surgical excision of all the lesions in the oral cavity was performed using electrocautery for gingivectomy procedure, while in the 2nd quadrant from 24 – 27, the excision was combined with internal bevel incisions with raising of the flap and recontouring of the gingiva with the final suturing and periodontal pack placement. Patient was informed about the tendency of the lesion to reoccur and was motivated to maintain oral hygiene since he had history of recurrence. Uneventful healing was seen at all the operated sites.(Figure 2) Patient was followed up for one year, no recurrence was found.

The present case is the rare case with the generalized pyogenic granuloma with no systemic involvement.

CONCLUSION:

Pyogenic granuloma is a benign lesion and does not attain an unusually large size. Generalized pyogenic granuloma is a rare occurrence, and there is limited published data about the same. Detailed patient history,

meticulous clinical examination, targeted surgical therapy and timely and regular patient follow ups will help achieve a satisfactory treatment outcome while good patient

compliance will definitely help in preventing recurrence of the lesion.

Figure 1a – pre-operative Generalized pyogenic granuloma: front view

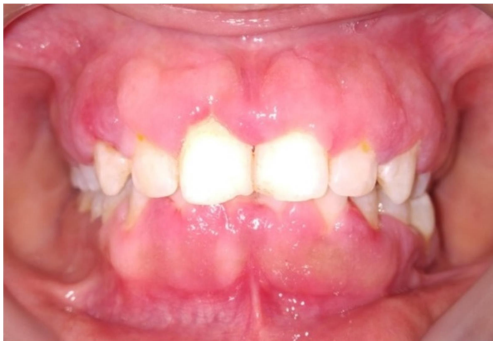

Figure 1b – Right lateral view

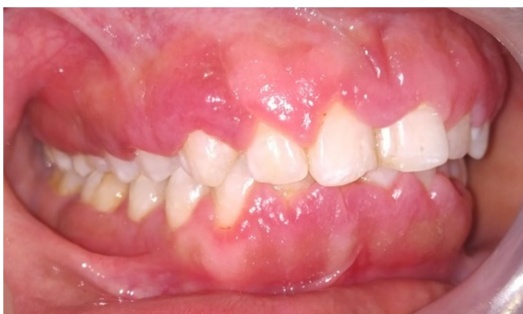

Figure 1c – Left lateral view

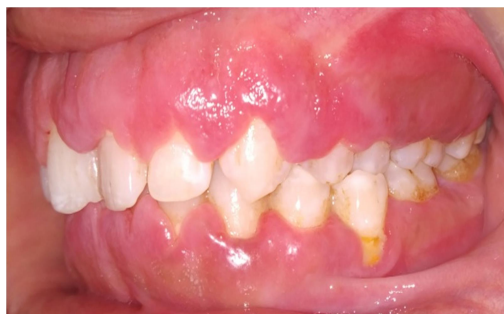

Figure 2 – post-operative: generalized pyogenic granuloma

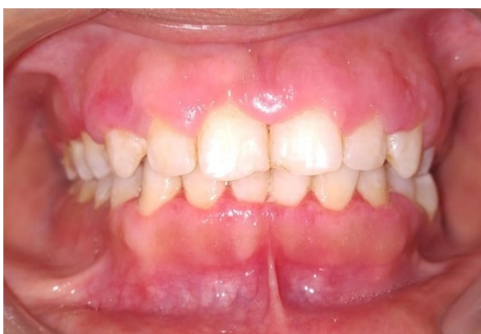

Figure 3 – Engorged blood vessels and extravasated red blood cells (hematoxylin-eosin);

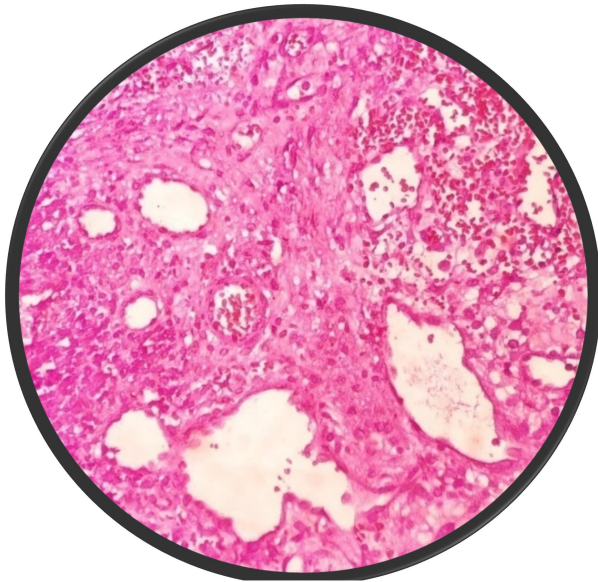


Figure 3a – Magnification 40X

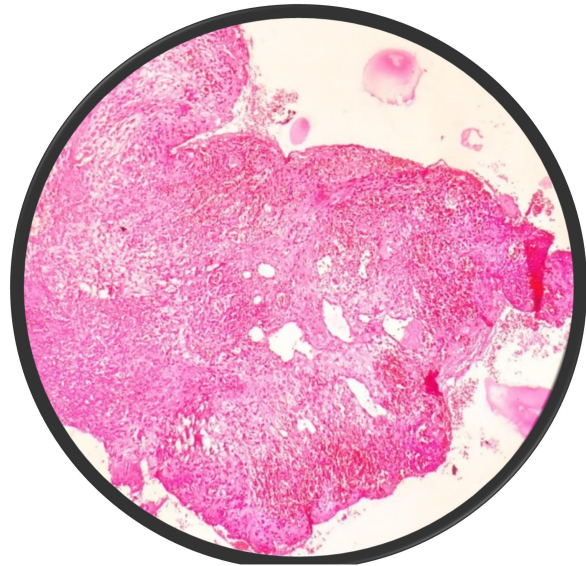
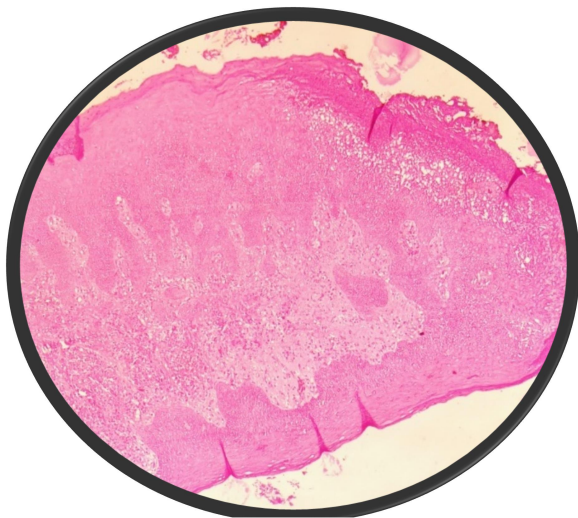


Figure 3b – Magnification 10X

Figure 4 – Stratified squamous epithelium showing ulceration and blunting of rete ridges along with plump stromal fibroblasts. (Magnification 10 X)



REFERENCES:

1. Shivaswamy S, Siddiqui N, Jain AS, Koshy A, Tambwekar S, Shankar A. A rare case of generalized pyogenic granuloma: A case report. Quintessence International. 2011 Jun 1; 42(6).
2. Perumal L. Intra Oral Multiple Pyogenic Granuloma-A Rare. Medical Science. 2014 Aug; 3(8).
3. Shetty AK, Wadkar P. Multiple Pyogenic Granulomas: A Case Report. Advances In Human Biology. 2015 Apr 30; 5(1):60-4.
4. Kamal R, Dahiya P, Puri A. Oral pyogenic granuloma: Various concepts of etiopathogenesis. Journal of oral and maxillofacial pathology: JOMFP. 2012 Jan; 16(1):79.
5. Leelavathy J, Ramesh SK, Christy AW. Generalized Gingival Pyogenic Granuloma in a 11 Years Old Female–A Diagnostic Challenge. Journal of Advances in Medicine and Medical Research. 2017 Jun 1:1-5.

Date of Publication: 30 December 2020

Author Declaration: Source of support: Nil, Conflict of interest: Nil

Plagiarism Checked: Urkund Software

Ethics Committee Approval obtained for this study? NA

Was informed consent obtained from the subjects involved in the study? YES

For any images presented appropriate consent has been obtained from the subjects: NA

Author work published under a Creative Commons Attribution 4.0 International License



Creative Commons Attribution
4.0 International License

CC BY 4.0

DOI: DOI: 10.36848/PMR/2020/12100.50475