

Case Report

“Gastric blow out” following Premature labour in a primigravida

*Dr. Ruchita Talreja¹, Dr. Padmakar K Baviskar², Dr. Pratik Gond³, Dr. Atreyee Sarkar⁴

1. Junior Resident, Department of Surgery, DBVPRMC, Pravara Institute of Medical Sciences (DU) Loni, Maharashtra.
2. Professor, Department of Surgery, DBVPRMC, Pravara Institute of Medical Sciences (DU) Loni, Maharashtra.
3. Junior Resident, Department of Surgery, DBVPRMC, Pravara Institute of Medical Sciences (DU) Loni, Maharashtra.
4. Junior Resident, Department of Surgery, DBVPRMC, Pravara Institute of Medical Sciences (DU) Loni, Maharashtra.
Corresponding author*



Abstract:

A 21-year-old primigravida presented with complaints of abdominal pain and distension for 8 days, accompanied with nausea, vomiting and fever with history of premature labour with still born baby of 27 weeks of gestation with provisional diagnosis of severe gastritis with ascites. Patient was admitted with Obstetrics and Gynaecology at Pravara Rural Hospital, Loni and managed symptomatically with stable general condition. Patient started deteriorating hemodynamically with hypotension, worsening general condition, progressive abdominal distension with increase in abdominal girth. Ryle's tube aspirate was bilious, quantity was 400 ml to begin with. Tracheal intubation done and she was resuscitated in the Intensive care unit (ICU). Patient was evaluated by surgical team and advised to undergo certain set of investigations. Ultrasound and chest x-ray were suggestive of hollow viscous perforation. CECT confirmed the presence of large rent in the posterior wall of stomach multiple air foci. Laparotomy was done and completely sloughed out gangrenous, thin walled (1mm) stomach was seen floating in the peritoneal cavity with no connection to pylorus and duodenum. Stomach excised completely and Feeding jejunostomy was done as a temporary measure. Definitive treatment was thought of as a later plan of management after initial stabilisation of patient. Along with the terrible clinical situation, we also had to deal with a completely other issue. And they were low socioeconomic position, illiteracy, and lack of awareness of the disease's danger. Young girl with such an uncommon clinical condition presents a number of difficulties for both the patient and the treating medical professionals. All of the intraoperative discoveries came as a complete surprise. Additionally, a review of the literature revealed that this clinical condition is extremely uncommon. The aforementioned illnesses should now be considered as a differential diagnosis for pregnant individuals presenting with acute stomach problems, and timely treatment should be given for the same to stop morbidity and death..

Keywords: Gastric perforation, antenatal gastric rupture, premature labour, diaphragmatic hernia.

Introduction

There aren't many non-traumatic stomach rupture cases that have been documented in literature. The most frequent causes of stomach rupture/perforation are ascariasis, gastric perforation, gastric ulcers, and previously undetected congenital defects. ¹A pre-existing, asymptomatic diaphragmatic hernia is worse by increased intra-abdominal pressure brought on by an enlarged uterus. Due to increased intra-abdominal pressure brought on by severe vomiting and an enlarged uterus during pregnancy, simultaneous gastric and diaphragmatic rupture can happen. It is a deadly yet uncommon pregnancy condition that usually occurs in the third trimester.

^{2,4,6} Patients who have had bariatric surgery before are more likely to experience gastric rupture later in pregnancy. ³ Patients who are pregnant and report with severe stomach pain throughout the antepartum, intrapartum, or postpartum phase should be suspected of this condition.

These patients need aggressive resuscitation and prompt management to reduce morbidity and mortality. Here we present a case of spontaneous gastric rupture (Total Blow out) in a young female who had premature labour with 27 weeks still born baby.

Case history

A 21-year-old primigravida presented with complaints of abdominal pain and distension for 8

days, accompanied with nausea, vomiting and fever with history of premature labour with still born baby of 27 weeks of gestation at Government Medical college of Maharashtra. Patient was provisionally diagnosed as having severe gastritis with ascites. She underwent ascitic fluid tapping on 12th August 2021. It showed a brownish coloured turbid fluid with small clots in it. Smear examination was suggestive of nonspecific inflammation. Patient was admitted with Obstetrics and Gynaecology at Pravara Rural Hospital, Loni on 17th August 2021 and managed symptomatically with stable general condition.

Vital data: Pulse 90/min, blood pressure of 110/70 mm Hg. RR 20/min. USG abdomen revealed no significant abnormality. Patient started deteriorating hemodynamically with hypotension, worsening general condition, progressive abdominal distension with increase in abdominal girth. Ryle's tube aspirate was bilious, quantity was 400 ml to begin with. Tracheal intubation done and she was resuscitated in the Intensive care unit (ICU). We, Surgeons, were called for examination of this patient at this point. Patient was evaluated by our team and advised to undergo certain set of investigations.

Table 1) Laboratory investigations(Preoperative)

Haemoglobin	13.1 g/dl
Total leucocyte count(TLC)	21700/mm ³
Platelet	1.18 lakhs/mm ³
PTINR	1.35
Serum Albumin	2.4
Serum Creatinine	0.5
Serum Urea	30
Serum Sodium	130
Serum potassium	5.0

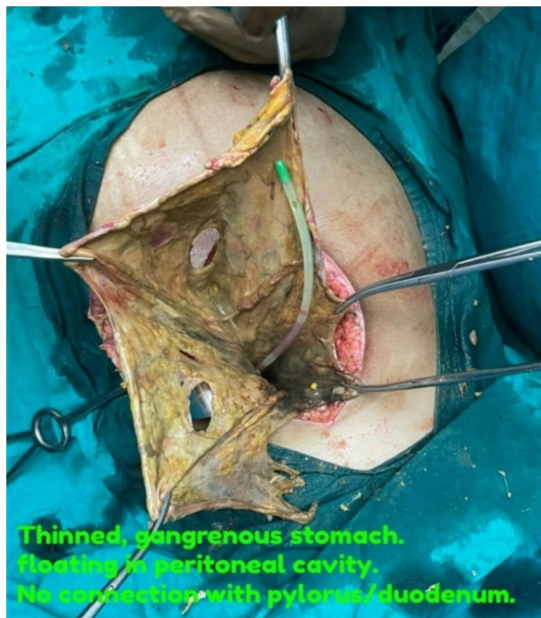

Figure No.1) Thinned, gangrenous stomach

Repeat ultrasound examination (portable done on 19th August) of abdomen and pelvis was suggestive of moderate ascites with fluid collection in

perihepatic, perisplenic and Morrison's pouch. In addition, 130 ml of fluid was seen in left pleural cavity. All the above findings were suspicious of hollow viscous perforation. Chest X-ray also supported the above diagnosis. To further confirm the diagnosis and find out additional important intra abdominal pathology. Contrast enhanced CT (CECT) scan was done. It confirmed the presence of tip of nasogastric tube lying free in general peritoneal cavity.

There was a large irregular rent measuring approx. 3-5 cm involving posterior wall of stomach with non visualisation of greater curvature with intraluminal contents communicating with intraperitoneal (free) fluid. Multiple intraluminal air foci present through out the abdomen. Also 4.5 x 3.5 cm size posterior diaphragmatic defect on left side through which a sac was seen herniating into thoracic cavity with the free fluid and multiple air foci was also reported.

Laparotomy was done which revealed a series of surprising, unexpected, serious intra -abdominal findings. Ryle's tube was floating free in the peritoneal cavity. Completely sloughed out

gangrenous, thin walled (1mm) stomach was seen floating in the peritoneal cavity with no connection to pylorus and duodenum as seen in the figure No. 1

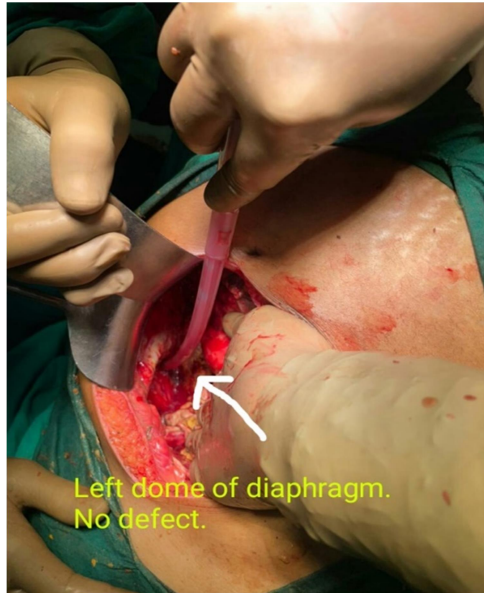

Figure No 2-Intraoperative diaphragm

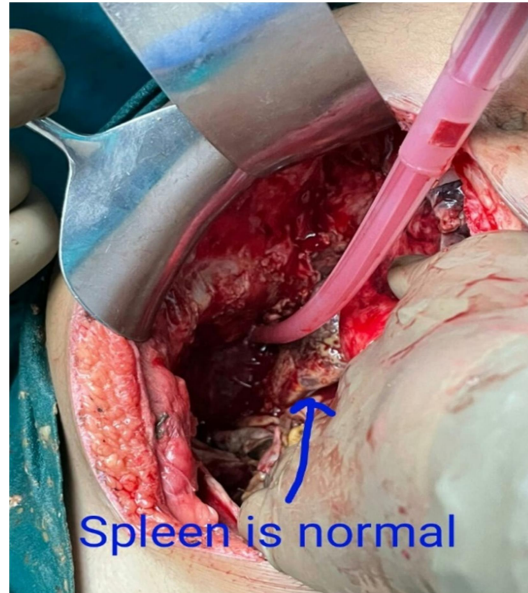


Figure No 3- Intraoperative spleen

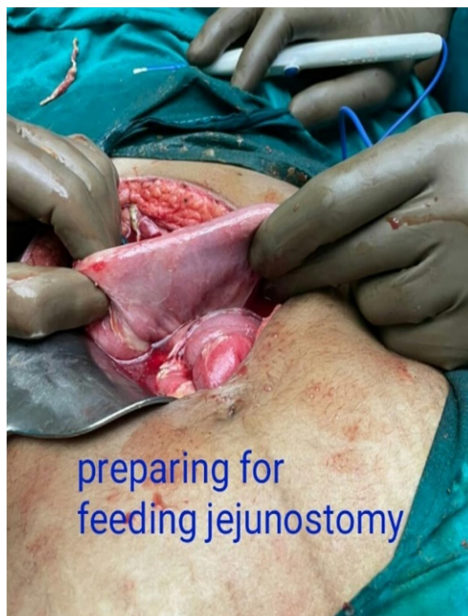

Figure No.4) Preparing for feeding Jejunostomy

Other abdominal viscera was plastered. Procedure done-Stomach excised completely. cardiac end closed in two layers. Since it was an unexpected finding, the patient was not fit to undergo definitive esophago-jejunostomy or any other more elaborate surgery. Feeding jejunostomy was done as a temporary measure. Available relatives(father & Mother) of patient were shown the morbid pathology and prognosis was explained. Patient was monitored in ICU postoperatively. Patient's general condition got stabilised gradually, vasopressor and ventilatory supports weaned off and tracheostomy tube kept in situ. The surgical site wound care was continued and parenteral nutritional support instituted. She developed midline wound gape on POD 5 and later on massive bilious discharge was noted. With suspicion of dislocation of jejunostomy tube. This was confirmed by a follow up CECT done on 25th POD.

Further plan of management was decided as follows-

Proper closure of cardiac end and oesophago-jejunostomy with construction of jejunal stomach. Patient remained unwilling in spite of convincing her about the definitive treatment which was proposed to be done free of cost. Unfortunately, She, along with the husband and other relatives, refused the treatment and patient was taken home to Nanded district. The reference letter describing her condition and operative procedure was given to her and we personally communicated to senior surgeon of GMC Nanded. Unfortunately she did not report there and was lost to follow up. Few weeks later we tried to trace the patient and it was found that she had succumbed to her illness in October 2021 at her residence itself.

Discussion

Gastric perforation is most commonly associated with advanced peptic ulcer disease(PUD) in the general population due to various, well established risk factors like smoking, chronic alcohol intake, non-steroidal anti-inflammatory drugs (NSAID's) and others. The study Ntirushwa et al. had compiled 9 cases of gastric perforation and rupture associated with pregnancy. Early intervention can decrease morbidity and mortality occurring due to peritonitis.¹

In a case report by Luu et al (2006), 33 weeks primigravida presented with respiratory and gastrointestinal complaints was suspected of

esophageal rupture. CT scan showed extravasation of dye into left pleural space. Intraoperative thoracotomy findings revealed necrotic cardia of stomach with 2 cm perforation with cardia herniating through 2 cm diaphragmatic defect. Necrotic part excised and perforation repair was done.²

Morcillo-Lo'pez (2010) et al also recorded a case of 37 year old primigravida with 15 weeks of gestation with known congenital diaphragmatic hernia confirmed on CT Scan. Both the diaphragmatic and gastric rupture were encountered during thoracotomy. Repair of both the defects done with uneventful pregnancy and caesarean section delivery at 38 weeks of gestation.⁵

Seon Cha et al (2002) reported a case consistent with the findings seen in our case. A primigravida patient with the 34 week still born baby presented with hypovolaemic shock in postpartum period with ultrasound findings of free intrabdominal fluid. Intraoperatively Gastric rupture seen and repair was done. The only differentiating feature from our case was congenital eventration of left hemidiaphragm.⁷

In a study by V.Srivastava (2010), 2 patients were reported with massive gangrene due to primary Antiphospholipid syndrome. Both the patients were pregnant females presenting with acute abdomen with hypotensive shock. Laparotomy revealing gangrene of stomach only. Total Gastrectomy with esophago-jejunal anastomosis was done in both the cases. The histopathological examination of both the gastric specimens revealed intramural thrombosis with inflammatory changes in the vessel wall suggestive of Antiphospholipid syndrome. The serology later showed elevated Anticardiolipin antibody titre. This condition, because of its grave prognosis, should therefore be thought of and evaluated in suspected patients.^{9,10}

Conclusion

Pregnancy with acute abdominal complains interfere with the interpretation of clinical features related to gastric rupture and lead to delayed diagnosis. Henceforth pregnant patients presenting with acute abdominal complaints the above conditions should be taken into consideration as differential diagnosis. The early management of the above condition must be done to avoid adverse maternal and foetal complications. The diagnosis of diaphragmatic and gastric conditions in early pregnancy can lead to better maternal and foetal

outcomes. Also the Antiphospholipid antibody syndrome should be taken into consideration as a differential diagnosis while evaluation of pregnant females with acute abdomen. The grave complications due to this syndrome can be prevented if diagnosed early in majority of such cases. The aim of reporting this case is to make clinicians aware of such a serious complication associated with pregnancy in young females. We faced an entirely different problem in addition to the serious clinical condition. And that was socio-economical status, illiteracy, lack of understanding of seriousness of the disease. In spite of treating this patient at a great monetary concession they refused to undergo definitive treatment. Such a young woman suffering from a near death complication was very depressing for the treating team. We tried to help her by arranging definitive treatment near her residential village but even then they did not report there. Health awareness

programmes, Mother-child health programmes are all being conducted in our state. They have yielded good results also. But this case re-emphasises that more aggressive, targeted efforts are still needed.

Patient Consent Declaration

Patient's relatives have consented to publish case report by taking all ethical precautions. The patient's relatives understand that though her name will not be published and that every attempt will be made to conceal her identities, anonymity cannot be guaranteed after certain extent.

Acknowledgement

The authors wish to thank the academic and executive managements of PIMS of PMT, Loni for their permission and active support, as mentioned in this article, to treat patients and carry out academic activities like scientific paper publications and oral presentations at relevant scientific fora.

References

1. Ntirushwa D, Rulisa S, Muhorakeye F, Bazzett-Matabele L, Rurangwa T, Small M. Gastric rupture in pregnancy: case series from a tertiary institution in Rwanda and review of the literature. *Am J Perinatol Rep.* 2016;6(04):e436-e441.
2. Alizadeh R, Aghsaiefard Z, Marzban-rad Z, Marzban-rad S. Pregnancy with diaphragmatic and stomach rupture: Lessons from a case-report. *Clin Case Rep.* 2020;8:1206–1208.
3. Policiano C, Rocha P, Catanho MC, Pinto L, Valentim-Lourenço A, Graça LM. Acute fetal asphyxia after gastric rupture in a pregnant patient with a gastric band. *Acta Obstet Gynecol Scand* 2013; 92(12):1419–1421
4. Luu TD, Reddy VS, Miller DL, Force SD. Gastric rupture associated with diaphragmatic hernia during pregnancy. *Ann Thorac Surg* 2006;82(5):1908–1910
5. Morcillo-López I, Hidalgo-Mora JJ, Baamonde A, Díaz-García C. Gastric and diaphragmatic rupture in early pregnancy. *Interact Cardiovasc Thorac Surg* 2010;11(5):713–714
6. Kohei Kawashima, Katsutoshi Nakahata, Takaaki Negoro, Koichi Nishikawa; "Spontaneous" Rupture of the Maternal Diaphragm. *Anesthesiology* 2013; 118:445
7. Seon Cha A, Krew MA, Tamlyn T, Gill P. Gastric rupture associated with pregnancy. *Obstet Gynecol* 2002;100(5 Pt 2):1072–1074
8. Christoph, R. F., & Pinkham, E. W. (1961). Unexpected Rupture of the Stomach in the Postpartum Period: A Case Report. *Annals of surgery*, 154(1), 100–102.
9. Srivastava, V., Basu, S., Ansari, M., Gupta, S., & Kumar, A. (2010). Massive gangrene of the stomach due to primary antiphospholipid syndrome: report of two cases. *Surgery today*, 40(2), 167–170.
10. Servera R, Piette JC, Shoenfeld Y, Font J, Bucciarelli S, Asherson RA. Registry of the European forum on antiphospholipid antibodies for patients with the "catastrophic antiphospholipid syndrome". European Forum on Antiphospholipid Antibodies. Accessible at: <http://www.med.ub.es/mimmun/forum/caps.htm>, Downloaded on 03 June 2022