

**QUIZ**  
**[Quiz No. 1, PMR Vol. 05 (1)]**  
**NEURORADIOLOGY**

AIRONI V D\*, GANDAGE S G\*, SACHDEV Y P\*, SHRIKANT N\*

### CASE HISTORY

A twelve year old female reported for MRI brain study. She had history of altered behaviour, personality changes and ataxia of one year duration. There was no history of fever or altered sensorium. She had history of measles like illness one year back, after which her symptoms deteriorated. A MRI scan was performed on 1.5 Tesla Philips Achieva Nova High gradient MRI scanner. The following MRI images show the underlying condition. **What is your diagnosis?**

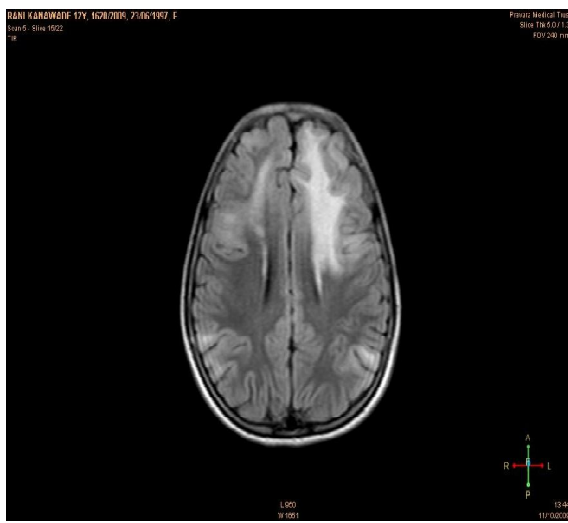


Fig 1: FLAIR axial image of the Brain

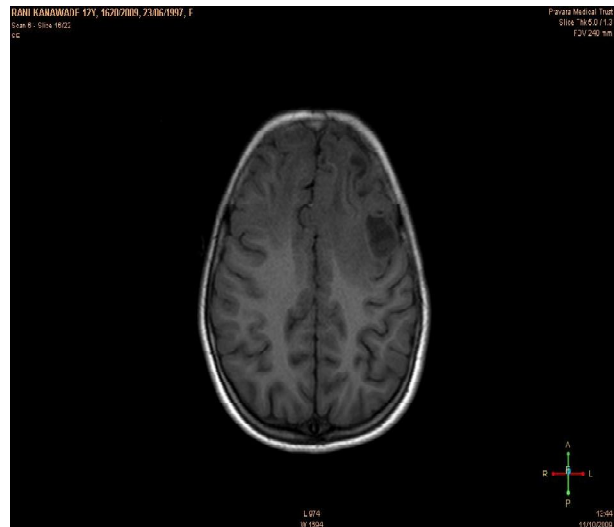

Fig 2 : T1 weighted axial image of the Brain

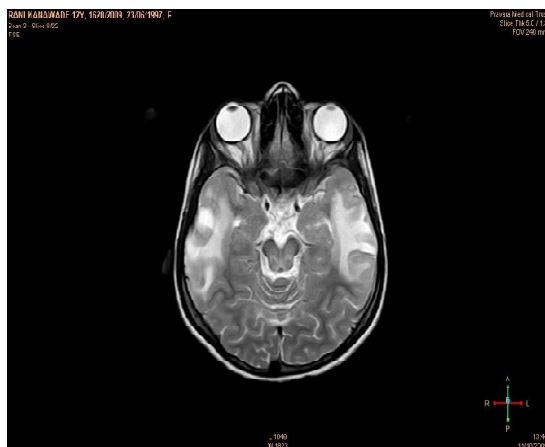

Fig 3 : T2 weighted axial image of the Brain

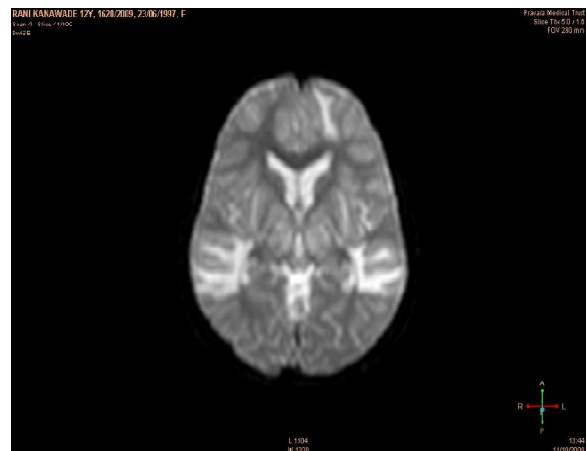

Fig 4 : Diffusion weighted image of the Brain

\* Dept of Radiodiagnosis, RMC, Loni.