

QUIZ
[Quiz No. 2, PMR Vol. 05 (2)]
NEURORADIOLOGY

Gandage S G*, Shetkar U B**, Aironi V D*, Sunil N K*

Case History

A twenty-two year old adult came in a state of unconsciousness after consuming dose of oral hypoglycemics by mistake. He had a history of psychiatric disorder and instead of anti-psychotics; he took oral hypoglycemics from medical stores. The blood sugar level then was about 20 mg%. MRI brain was advised and revealed some positive findings. The MR images are as follows:

What is the positive finding? What is your conclusion?

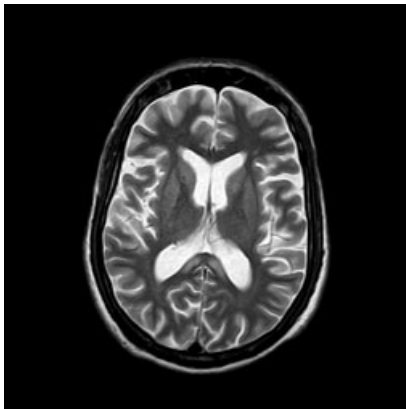


Fig 1: Axial T2 weighted image at the level of corpus callosum

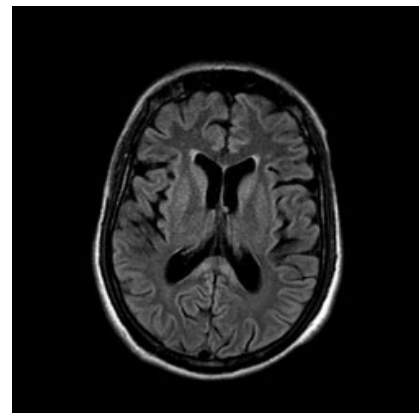


Fig 2: Axial FLAIR image at the same level

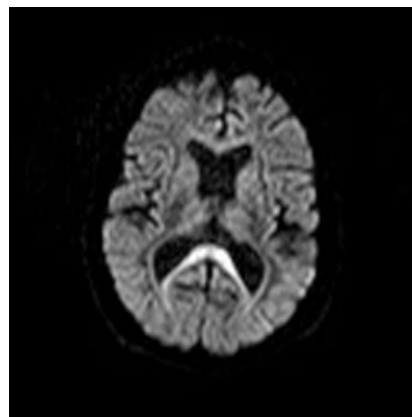


Fig 3: Corresponding Diffusion weighted image of Brain

* Dept of Radiodiagnosis, RMC, Loni.

** Dept of Medicine, RMC, Loni