

Successful Pregnancy Outcome Following Treatment of Gestational Choriocarcinoma

Bangal V*, Kwatra A**, Sali Bhushan***

Abstract

Choriocarcinoma is a highly malignant trophoblastic tumour that follow either a normal pregnancy, abortion or ectopic pregnancy. The risk is immeasurably greater following hydatidiform mole. We report the case of a young woman who presented with gestational choriocarcinoma following repeated hydatidiform molar pregnancies. After thorough assessment of risk factors, combination chemotherapy in the form of MAC-FAC regimen was given for six cycles. The woman showed good compliance regarding regular follow ups and contraceptive advice for a period of two years, following which she became pregnant and gave birth to a healthy baby.

Key words: Choriocarcinoma, β -hCG, MAC-FAC regimen.

Introduction

Choriocarcinoma is a highly malignant tumor arising from the chorionic epithelium. Approximately half cases of persistent gestational trophoblastic neoplasia follow hydatidiform mole, 25 percent follow an abortion, and remaining develop after an apparently normal pregnancy.^[1] The characteristic gross picture is that of a rapidly growing mass invading both myometrium and blood vessels that causes hemorrhage and necrosis. An important diagnostic histological feature of choriocarcinoma is the absence of a villous pattern. Most common metastatic sites are lungs, vagina, vulva, kidneys, and brain. Gestational trophoblastic neoplasia whether occurring in a low or high risk group, are highly sensitive to chemotherapy.

Case report

A 20 year old nullipara with history of 2 consecutive abortions, came on 12th May 2005, with complaints of irregular menses with spotting for 15-20 days since one and half year, pain in lower abdomen and low backache since two months and evening rise of temperature since seven days. She was married two years back. She had undergone first trimester medical termination of pregnancy (MTP) for severe jaundice, one and half year back. Six months after MTP, she was diagnosed as a case of hydatidiform mole at 6 weeks gestation for which she underwent dilatation and curettage. Following evacuation, she had continuous vaginal bleeding. Dilatation and curettage was repeated after fifteen days. She again underwent, suction evacuation at 10 weeks gestation as she was again diagnosed as having H. mole. Histopathological report confirmed the diagnosis of hydatidiform mole. On examination her vital parameters were stable. She had sick look, gross pallor was present with no icterus or lymphadenopathy. Mild tenderness was present on right side of the lower abdomen. Cervix and vagina were healthy. On per speculum examination. uterus was bulky. A mass of 4 × 5 cm² was felt on right side of uterus which was separate from the uterus. Pelvic ultrasound examination

* Professor, Dept of Obs & Gynae, RMC, Loni

** Assist Prof, Dept of Obs & Gynae, RMC, Loni

** Tutor, Dept of Obs & Gynae, RMC, Loni

Address for correspondence:

Dr V. Bangal, Professor, Dept of Obs & Gynae, RMC, Pravara Institute of Medical Sciences, Loni
Email: vbb217@rediffmail.com

revealed a 9.2×7.0×4.5 cm, heterogenous mass invading myometrium and parametrium, involving right uretero-vesical junction causing hydronephrosis; suggestive of locally advanced choriocarcinoma without distant metastasis. Her urine pregnancy test was positive. Her serum β hCG level on admission was 5570 mIU/ml. Diagnostic curettage

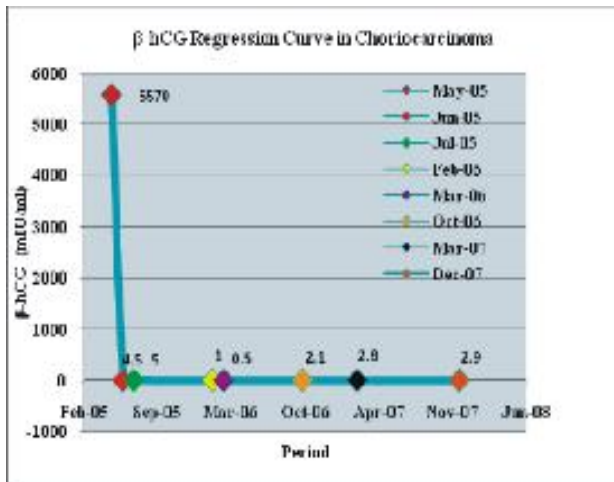


Fig 1: Serial estimation of β -hCG

of the endometrium confirmed the diagnosis of gestational choriocarcinoma. On careful risk assessment, it was found that she belonged to low risk group. Combination chemotherapy was started in the form of MAC-FAC regimen. Methotrixate 1mg/kg, Actinomycin-D 12 μ g/kg and Cyclophosphamide 3mg/kg was given on day 1, 3 and 5. On day 2 and 4; Calcium Folate 0.1mg/kg, Actinomycin-D 12 μ g/kg and Cyclophosphamide 3mg/kg was given. On completion of first cycle of chemotherapy, β -hCG levels decreased to 680mIU/ml. Pelvic ultrasound revealed regression in the tumour size by half. Course of chemotherapy was repeated every fourteen days for six cycles. Serial estimation of β -hCG showed steady decline with level of 2.8mIU/ml on 28th December 2007 (Fig. 1). Pelvic ultrasound showed complete disappearance of the mass. The patient and relatives were regularly counseled regarding importance of

chemotherapy, contraception and regular follow up. Patient and relatives showed good compliance.

After one year of stoppage of chemotherapy, patient reported with eight weeks of amenorrhea. Obstetric ultrasonography revealed a single, live, intrauterine gestation of 7 weeks and 3 days. With the diagnosis of early pregnancy, she was vigilantly followed for ruling out the possibility of any complication that may occur following chemotherapy for choriocarcinoma. Fetal anomaly scan was done at 18 weeks and was found to be normal. She was advised regular antenatal visits and obstetric ultrasonography. She got admitted on 28th April 2009 with labour pains. Augmentation of labour was done with oxytocin. A male baby of 2.8 kg was delivered vaginally with Apgar score of 7, 8, 9. Intrapartum and postpartum period was uneventful. Placenta was sent for histopathology and was found to be normal. Both mother and baby were discharged on fifth postnatal day. Mother and baby attended postnatal and well baby clinic. Baby was devoid of any complications till six months of age.

Discussion

Occurrence of choriocarcinoma following hydatidiform mole (HM) is a well recognized entity. Saleem A, Masoom K^[2] in their study have reported that, as many as 18.0% (29/65 cases of HM) of hydatidiform moles had shown progression to invasive mole or choriocarcinoma. In order to preserve the reproductive potential of young women with choriocarcinoma and invasive mole, chemotherapy alone was given without hysterectomy in 265 cases. In a study done by Song H Z, Wu P C.^[3] They reported that, 205 cases had become pregnant after recovery, with a total of 355 pregnancies. These data indicate that treatment of malignant trophoblastic neoplasm with chemotherapy alone is compatible with the preservation of fertility in most women. Majority of women have experienced regular menstrual cycle within six months of completing last chemotherapy cycle [almost all, 100.0% (n=57)], or became pregnant if they wished to. Study further revealed that 95.0-97.0%

women desirous of pregnancy were able to conceive and 86.0%^[4] had at least one live birth. Shahgufta Shaheen, Shahnaz Akhtar reported a case of choriocarcinoma who had undergone right salpingectomy and completed 5 courses of MAC regimen. She conceived one year after completion of chemotherapy.^[5] Methotrexate and Actinomycin-D appear to have no adverse effects on fetal growth. These reports show that a normal menstruation and uncomplicated term delivery can be expected after complete chemotherapy for gestational trophoblastic neoplasia (GTN).

Conclusion

Gestational choriocarcinoma is a lethal, fast growing malignant tumour of uterus. It can be cured by appropriate fertility preserving technique i.e. chemotherapy. Regular follow up and barrier contraception for two years following chemotherapy is advised. Return of fertility is comparable with the general population of the same reproductive age. These women can have good pregnancy outcome following proper antenatal care. There appears to be no increase in fetal congenital malformation and chromosomal aberrations following chemotherapy for choriocarcinoma.

References

1. Haemorrhage in early pregnancy, D. C. Dutta, Textbook of Obstetrics, Sixth Edition, Calcutta. New Central Book Agency, 2004: 159-202.
2. Saleem A, Masoom K. A case of consecutive molar pregnancies followed by choriocarcinoma. J Coll Physicians Surg Pakistan 2003; 13: 161-3.
3. Song HZ, Wu PC, Wang YE, Yang XY, Dong SY. Pregnancy outcomes after successful chemotherapy for choriocarcinoma and invasive mole: long-term follow-up. Am J Obstet Gynecol. 1988 Mar; 158(3.1):538-45.
4. Hsieh FJ, Chen TC, Cheng YT, Huang SC, Hsieh CY, Ouyang PC. The outcome of pregnancy after chemotherapy for gestational trophoblastic disease. Biol Res Pregnancy Perinatol 1985; 6: 177-80.
5. Shahgufta Shaheen, Shahnaz Akhtar. Successful pregnancy outcome following chemotherapy for Choriocarcinoma. J Postgrad Med Inst Apr -Jun 2007; 21(2): 154-5

