

Unusual variation of the renal vessels – A case report

Chavan S K*, Wabale N R*, Daimi R S**

Abstract

The renal vessels typically originate from the aorta at the level of L2 vertebra below the origin of the superior mesenteric artery. Both vessels then course anterior to the renal pelvis before entering the renal hilum. The incidence of variation of renal arteries, (aberrant or accessory), is about 30%. They arise from the aorta or iliac arteries, anywhere from the level of T-11 to L-4. Usually the accessory arteries course into the renal hilum to perfuse the upper and lower polar regions. We present a case in which anomalies were found in both renal vessels and kidneys. Right kidney had three blood vessels i.e. lower, middle and upper. On left side, the kidney was lobulated and it had two aberrant vessels, one at the lower pole and other at upper. Knowledge about unusual variations of the renal vessels is necessary for selection of kidney donor as well as during nephrectomy and segmental resection.

Key words : Unusual variation, Renal vessels, Renal transplant

Introduction

Normally there is a single renal artery and vein for each kidney which is situated at the hilum. Right renal artery passes horizontally, anterior to the right crus of the diaphragm and behind the inferior venacava to reach the hilum. Before reaching the hilum of the kidney the artery divides into four or five branches. Right kidney is drained by one renal vein which lies in front of the renal artery and passes medially to drain into the inferior venacava. The left kidney is also supplied by a single renal artery and a single renal vein; the vein passing anterior to the artery and then

passing medially, crossing the aorta to drain into the inferior venacava. Unusual vascular patterns are the most often encountered variations among renal morphological variations. Renal vessels, especially arteries, exhibit a high degree of variation.^[1] Variations among the renal veins are not as common as arteries (incidence - 0.8 to 6%). Variations occurring in both arteries and veins together have not been reported. Most of these variations remain undiscovered unless surgical procedures, arteriography or venography are undertaken. When identified, documentation is essential as it holds many surgical and therapeutic implications. In the present case variations were found both in renal artery and vein, bilaterally.

* Professor, Dept of Anatomy, RMC, Loni

** Assist Prof, Anatomy, RMC, Loni

Address for correspondence:

Dr S.K.Chavan, Professor, Dept of Anatomy, RMC, Pravara
Institute of Medical Sciences, Loni
Email: anatomy@pmtpims.org

Case report

During routine dissection of an adult male cadaver in the Department of Anatomy, variations in renal vascular pattern was observed. The area was cleaned

and properly dissected. The arteries were coloured with red and veins with blue marker and photographs taken in-situ. The specimen was taken out and then photographed again.

Right Kidney

The right kidney was supplied by three arteries originating from the aorta and three corresponding veins were seen draining into the inferior vena cava. The upper vessels were at upper pole, the middle at the hilum of the kidney and lower ones at the lower pole of the kidney. The artery at the upper pole coursed behind the inferior vena cava, but the middle and lower were seen coursing superficial to the inferior vena cava. Both middle and lower vessels ran behind the pelvis of the ureter (Fig.1). Normally the lower pole of the right kidney extends up to the center of the body of L3 vertebra. In the present case however the lower pole of right kidney was at L4 level.

Left kidney

The upper vessels were seen between upper pole and upper part of the hilum. The lower vessels entered at the lower part of the hilum (Fig 1) and ran behind the pelvis of the ureter (Fig.2). Usually the left kidney at a slightly higher level than the right but in the present case , lower pole of the

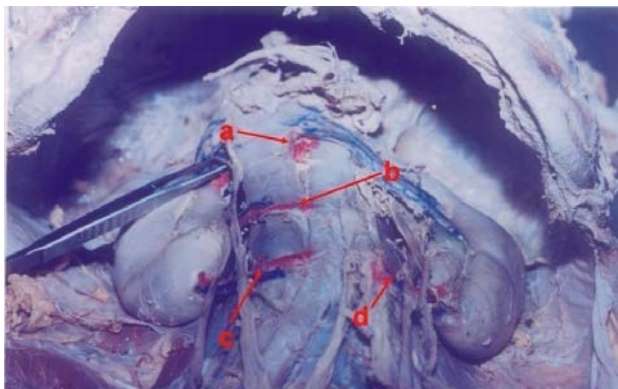


Fig 1 : Showing multiple renal arteries and veins.
 a. Renal artery at upper pole of right kidney
 b. Middle renal artery of right kidney
 c. Renal artery at lower pole of right kidney
 d. Renal artery at lower pole of left kidney

right kidney was at L4 level and that of the left kidney was slightly lower than that.

Discussion

During development the kidney first lies in sacral region as it develops from the metanephros receiving its blood supply from the lateral sacral arteries, but differential growth of abdominal wall

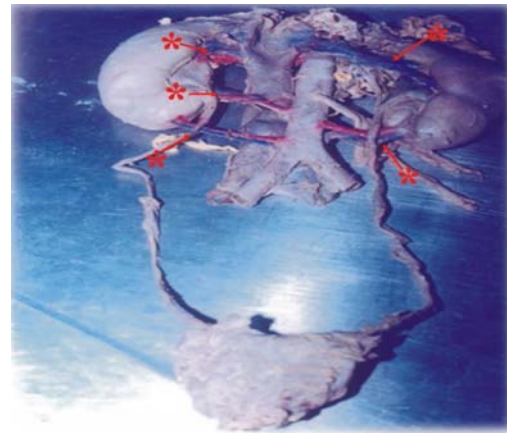


Fig 2: Showing relation of pelvis of ureter to multiple renal vessels.
 * Multiple renal veins.

causes the kidney to ascend up to the lumbar region. With its ascent, higher branches of aorta take over the blood supply. The definitive renal artery represents the lateral splanchnic branch of aorta at the level of the second lumbar segment. The persisting artery other than this is called the accessory renal artery. It arises from the aorta or iliac arteries anywhere from the level of T₁₁ to L₄.^[2] Occurrence of aberrant renal arteries are seen in up to 30% of individuals. Almost a third of such kidneys receive two or more of these so called accessory renal arteries. It occurs as often on one side as on the other^[3]. The reason given by embryologist is that these arteries are secondary to the delayed ascent of the kidney. The accessory renal arteries are considered precociously formed remnants of the embryonic lateral splanchnic series of arteries.^[4] In the present case is possible that the incomplete

ascent of the kidneys that led to the persistence of lower branches from the aorta and the addition of new arteries at the upper level was in anticipation of further ascent of the kidneys.

Most branches of renal arteries and most tributaries of the renal veins pass through the hilum of the kidney. Branches that do not pass through the hilum are also commonly seen and are called extrahilar arteries. They penetrate the parenchyma of the kidney on their external surface. They are particularly frequent at the upper pole as in the present case (seen in both right and left kidney). Their unexpected presence may affect operative procedures. When multiple arteries are present, each supplies a distinct segment of the kidney. As there is no collateral perfusion, occlusion of one artery will result in infarction of its associated segment.

These so called renal arteries may be extrahilar or hilar and cannot be truly called accessory to normal renal vasculature as they do not anastomose with segmental arteries. Multiple renal veins are almost as frequent as multiple renal arteries on the right side and are infrequent on the left side, but in this case the anomaly was found on both sides. The left renal vein may bifurcate and pass in front and behind the aorta in the form of circumaortic ring or it may have no anterior connection at all or it may pass behind rather than in front of the aorta and drain into the inferior vena cava, and the lower vein may pass behind the ureter and the aorta to drain into inferior vena cava.^[2] The renal veins are interconnected within the kidney and if one renal vein is occluded the remaining renal vein will continue to drain the entire kidney. Unlike the arteries the venous tributaries anastomose within the kidney and there are minor anastomosis throughout the fibrous capsule with veins that are not tributaries of renal veins, but due to insufficiency of anastomosis, sudden occlusion of a vein may cause necrosis of the whole kidney.^[3]

Applied Anatomy

Knowledge of the variations of the renal vessels has grown in importance with increasing numbers

of vascular anastomosis in renal transplant surgeries, laproscopic surgeries, and for various different radiological and surgical techniques being used in recent years.

In a majority of such cases, where multiple renal vessels are present, the donor is unfit surgery due to technical difficulties of surgical intervention as well as for post-operative management. Laproscopic surgical procedure requires knowledge of additional renal vessels in order to avoid complications like complete necrosis of a particular segment of the kidney.^[3] Possibilities of additional vessels should also be kept in mind while performing noninvasive diagnostic procedures. The additional vessels may lead to alarming hemorrhage if unnoticed during total nephrectomy.^[5]

References

1. Sykes D.: The arterial supply of the human kidney with special reference accessory renal arteries. Br. Jr. Surg. 1963; 50: 368-370.
2. Embryology and development, In: P.L. Williams, L. H. Bannister M.M. Berry P. Collin, M. Dyson, J. E. Dussek and M. W. J. Ferguson, eds Gray's Anatomy 36th ed, London, Churchill Livingstone (1995), 91-318.
3. The Posterior Abdominal wall and its associated organs, In: W. Henry Hollinshead, Cornelius Rosse, eds Text book of Anatomy. Harper and Row, Publishers. 707-708.
4. Urinary System, In: P.L. Williams, L. H. Bannister M.M. Berry P. Collin, M. Dyson, J. E. Dussek and M. W. J. Ferguson, eds Gray's Anatomy 36th ed, London, Churchill Livingstone (1995), 1814-1844.
5. Narendiran Krishnasamy, Mohardan Rao KG and et al: An unusual case of unilateral additional right renal artery and vein. International Journal of Anatomical variations, 2010; 3: 9-11.