

## Multiple odontogenic keratocysts with diverse histologic features in a non-syndromic patient

Rudagi B M\*, Kharkar V R\*, Kini Y\*\*

### Abstract

*An exceptional case of multiple odontogenic keratocysts in a 21 year old female in non-syndromic patient associated with impacted third molars has been reported. Patient had pain and swelling in the left angle of mandible since last 2 years. Intraoral examination revealed buccal cortical plate expansion in the angle region of mandible. An OPG revealed bilateral radiolucency in the angle region of mandible. The patient was investigated and treated with surgical enucleation of the cyst followed by the application of Carnoy's solution. The patient showed uneventful recovery with no recurrence after a follow up of one year. Histopathology revealed diverse histological features on both sides.*

**Keywords:** Keratocyst, Odontogenic cyst, Multiple cysts, Diverse histology.

### Introduction

The term odontogenic keratocyst was introduced by the oral pathologists in Europe in the mid 1950's, to denote a cyst with specific histological behavior. In earlier literature, the keratocyst was described as a cholesteatoma. Odontogenic keratocyst has a keratinized lining and the cyst arises from the cell rests of dental lamina rather than from reduced enamel epithelium or the cell rests of Malassez. Odontogenic keratocyst may occur at any age but is rare below 10 years of age. Mandible is more affected than maxilla and is common in the ramus third molar area. The associated symptoms include pain and soft tissue swelling. Multiple odontogenic keratocyst are associated with syndromes such as Basal Cell Nevoid Syndrome usually in younger patients. An exceptional case of multiple odontogenic keratocysts in a non-syndromic patient associated with impacted third molars has been presented. These cysts that were enucleated followed by the application of Carnoy's solution were found to have diverse histopathology.

\* Professor, Dept of Oral & Maxillofacial surgery, RDC, Loni

\*\* Lecturer, Dept of Oral & Maxillofacial surgery, RDC, Loni

### Address for correspondence:

Dr B.M.Rudagi, Professor, Dept of Anatomy, RMC, Pravara Institute of Medical Sciences, Loni

Email: bmrudagi@rediffmail.com

### Case report

A 21-year-old female patient reported with swelling and pain in the left angle of mandible. The swelling was initially small and was painless and gradually increased to present size. There was no pain or swelling in the right side of angle of mandible. Extra oral examination revealed a diffuse swelling on left side of mandible in the angle region, which was tender on palpation. Intraoral examination revealed buccal cortical expansion at the same site of the mandible & there were no skin lesions suggestive of basal cell nevus syndrome.

### Investigations

An Orthopantomograph was advised and it revealed a well defined radiolucency extending from distal aspect of left lower first molar involving the angle, ramus and the coronoid process of mandible wherein, the third molar tooth was displaced to the neck of condyle (Fig 1). Inadvertently, the right side also revealed a well-defined multilocular radiolucency extending from the angle to the ramus of the mandible with an impacted third molar. A bilateral incisional biopsy led to the diagnosis of an odontogenic keratocyst.

### Histological features

The left cyst was parakeratinized type, wherein the H & E sections revealed cystic lining composed of

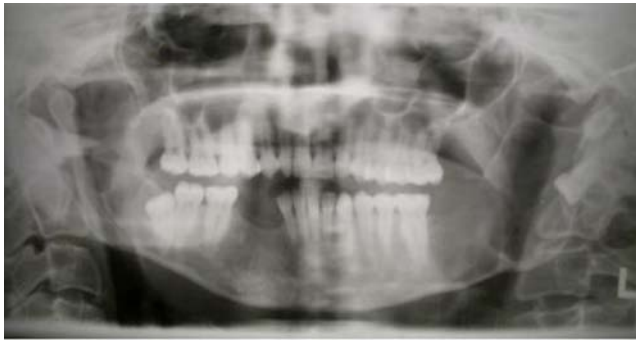

Fig 1 : OPG Showing bilateral well defined radiolucency in the angle, ramus and coronoid process with displaced 3<sup>rd</sup> molar on left side

uniform layers of stratified squamous epithelium of 6-8 cells thickness. The luminal surface had flattened parakeratotic epithelium cells, exhibiting wavy surface appearance. The basal cell epithelial layer was composed of palisaded layers of hyper chromatic columnar epithelial cells (Fig 2).

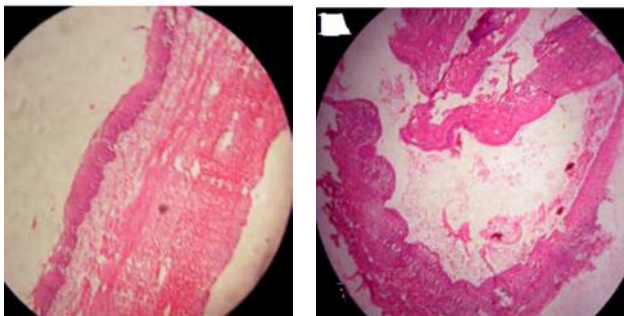


Fig 2: slide showing diverse histological features; one is orthokeratinized(left side) and other is parakeratinized(right side).

The right cyst was orthokeratinized type, wherein the H & E sections revealed cystic lining composed of stratified squamous epithelium with an orthokeratotic surface of varying thickness. Cystic lumen showed flakes of orthokeratin, which matched with the cheesy material observed on gross examination.

### Management

Under General anesthesia, the left & right sided cystic lesions were enucleated along with the

lower third molars to which the cystic lining was adherent, followed by application of Carnoy's solution ( Fig 3).

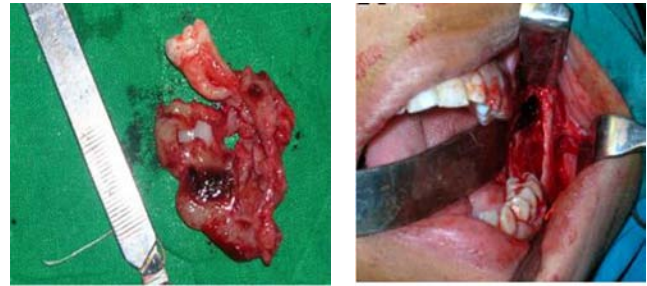


Fig 3: shows cystic lining after enucleation.

### Discussion

The odontogenic keratocyst is an epithelial developmental cyst of the jaw.<sup>[1]</sup> Some surgeons believe the cyst can be properly treated with enucleation if the lesion is removed intact.<sup>[2,3]</sup> However, complete removal of the OKC can be difficult because of the thin friable epithelial lining, limited surgical access, skill and experience of the surgeon, cortical perforation, and the desire to preserve adjacent vital structures.<sup>[4]</sup>

An odontogenic keratocyst may envelope an adjacent impacted tooth (envelopental keratocyst).<sup>[5]</sup> Very occasionally the lining of a cyst in a true dentigerous relationship may be identical to that of an odontogenic keratocyst.<sup>[6]</sup> Altini et al<sup>[7,8]</sup> termed this as follicular primordial cyst (follicular keratocyst).

An odontogenic keratocyst associated with an impacted third molar appears to arise at a younger age and grow more rapidly than a cyst unrelated to an impacted tooth & may affect the proliferation of an adjacent odontogenic keratocyst.<sup>[9]</sup>

Recurrence is common in infected cysts than in non-infected cysts. Based on the high rate of recurrence, most authors advocate radical enucleation for small unilocular keratocysts and suggest resection & bone grafting for very large lesions. Advocates of conservative management of large multilocular odontogenic keratocysts outline some technical difficulties in attempting the

complete enucleation due to the limited access to the depth of the mandible.<sup>[11]</sup> Extensive resection of the mandible with its high morbidity maybe too radical for large odontogenic keratocysts and even an over-treatment. In any case clinical and radiological follow-up is mandatory for years after surgery because recurrence may occur even years later. Our patient is on regular follow up and till date showed no signs of recurrence.

### References

1. Marx RE, Stern D: Oral and Maxillofacial Pathology: A Rationale for Diagnosis and Treatment. Chicago, IL, Quintessence, 2003, pp 590-601.
2. Mieselmann F: Surgical management of the Odontogenic Keratocyst: Conservative approach. Journal of Oral & Maxillofacial Surgery 52: 960, 1994.
3. Williams TP, Connor FA: Surgical management of the Odontogenic Keratocyst: Aggressive approach. Journal of Oral & Maxillofacial Surgery 52: 964, 1994.
4. Teresa AM, Christopher CB, Fang Qian: A retrospective review of the treatment of the odontogenic keratocyst. J Oral & Maxillofacial Surgery 63; 635-639.
5. Kramer IRH, Pindborg JJ, Shear M, editors. Histological typing of odontogenic tumors, 2<sup>nd</sup> edition. Berlin: Springer Verlag; 1992. p.35-6.
6. Shear M. Developmental odontogenic cysts. An update. J Oral Pathol Med 1994; 23:1-11.
7. Altini M, Cohen M. The follicular primordial keratocyst (odontogenic keratocyst). Int J Oral Surg 1982; 11: 175-82.
8. Altini M, Cohen M. Experimental extra-follicular histogenesis of follicular cysts. J Oral Pathol 1987; 16: 49-52.
9. Goichi T, Takahide M, Takeshi K et al: A comparative study of odontogenic keratocysts associated with and not associated with an impacted mandibular third molar. Oral Surg Oral Med Oral Pathol Oral Radiol Endod 2002; 94:272-5
10. Main, D.M.G: Epithelial jaw cysts. Br. J. Oral Surg. 1970: 8: 114-125.
11. Michelle G, Giovanni BG, Carlo J et al: Conservative management of a large Odontogenic Keratocyst: Report of a case & Review of Literature; J Oral Maxillofacial Surg 64: 308-316, 2006

