

## Malignant Fibrous Histiocytoma Of Vulva

Surekha A Tayade\*, Poonam V Shivkumar\*\*

### Abstract

*Malignant Fibrous Histiocytoma of Vulva is an exceedingly rare tumor of the female genital tract. MRI is the imaging method of choice. The most conclusive diagnosis is by histopathological examination which shows spindle cells with focal myxoid or storiform pattern of cells. Treatment modalities include chemotherapy and radiotherapy or a combination of these with surgery. Such a rare case, considered inoperable at first but being treated adequately subsequently is reported.*

**Key Words:** Malignant, Fibrous Histiocytoma, Chemotherapy

### Introduction

Malignant Fibrous Histiocytoma (MFH), described by O'Brien and Stout in 1964, is the most common soft tissue sarcoma of late adult life accounting for 20-24% of soft-tissue sarcomas.<sup>[1,2]</sup> It usually occurs in the extremities of elderly patients, but has also been seen in a number of other sites.<sup>[3]</sup> However MFH in female genital tract is exceedingly rare. Primary Sarcomas of the Vulva account to 1.8 – 3% of all vulvar malignancies.<sup>[4,5]</sup> The most common vulvar sarcoma is leiomyosarcoma. Malignant fibrous histiocytoma occurs infrequently on the vulva but nonetheless is the second most frequent sarcoma of this region. It is a malignant tumor capable of metastasizing by hematogenous and lymphatic routes. The therapy of choice is radical surgery. It presents as a rapidly growing painful or ulcerated mass. We are presenting a case of Vulval Malignant Fibrous Histiocytoma which on clinical

### Case Report

A 40 years old, married, infertile woman, presented with nodular lesions on the vulva and discharge from the lesions since 3 years. She was cachexic, afebrile, pale, anicteric, with stable vitals. Two non tender inguinal lymph nodes were palpable on left side 2x2 cm in size placed transversely. There was no pedal edema. Breast

examination was normal. Cardiorespiratory examination was normal. Abdomen was soft, with no organomegaly. Local examination revealed multiple tender nodular lesions on the vulva. 5 lesions were seen of 2x3 cms, 4 being attached by surface skin tags and freely mobile. One was apparently stuck to the pubic symphysis with pus discharge from the lesion. This particular lesion was hard and base was giving the appearance of being stuck to the bones. Speculum examination revealed a healthy cervix and vagina. Bimanual examination revealed a normal size, retroverted, retroflexed uterus. Bilateral fornices were free. Probable diagnosis of Vulval malignancy was kept, operability at this time being improbable. On investigations, haemoglobin - 10 gm/dl, total counts – 5000/mm<sup>3</sup>, FBS - 103 mg/dl and PPBS - 129 mg/dl, liver and kidney function tests were normal, VDRL and HIV - non reactive, Chest X-ray was within normal limits. Ultrasonography Abdomen was normal and that of Pelvis showed a normal sized uterus with endometrial thickness of 3 mm. Both ovaries were normal. Scrape cytology from the lesions showed acute inflammatory exudates. Examination under anaesthesia was done and wide excision of all the lesions hanging with skin tags was done. However, from the lesion which was fixed only biopsy was taken. Histopathological examination revealed Intermediate Grade Spindle Cell Sarcoma with focal myxoid and storiform areas suggesting features of Malignant Fibrous Histiocytoma (Fig1). In view of lesion being stuck to the pubic symphysis plain X-ray pelvis was done and

\* Associate Professor, Dept. of Obs & Gynae, MGIMS, Sewagram

\*\* Professor, Dept. of Obs & Gynae, MGIMS, Sewagram

#### Address for correspondence:

Dr Surekha Atul Tayade, Department of Obs and Gyne, MGIMS, Sewagram - 442102, Wardha, Maharashtra, India  
E mail: surekhatayademgims@yahoo.co.in

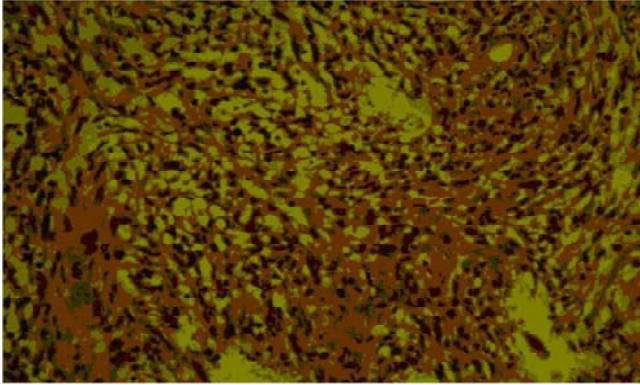


Fig 1: Microphotograph showing Intermediate Grade Spindle Cell Sarcoma with focal Myxoid storiform Areas suggesting features of Malignant Fibrous Histiocytoma (100x)

showed no secondaries. This gave us some hope and as the woman was only 40 years old, though she could not afford MRI, we could still get the MRI done through the cancer relief fund. MRI did not show secondaries in the pelvic bones. A definite plane was visible in between the vulva lesion and pelvic bone.

The woman was started on broad spectrum antibiotics and the discharging wound was irrigated with metrogyl solution and dressed daily. Within 8 days the wound was healthy looking. Patient was given Inj. Ifosfamide and Inj. Adriamycin. one cycle in view of reducing the bulk and improving mobility. After a gap of 15 days the woman was reexamined and now the lesion was such that surgery could be planned. Radical Vulvectomy with bilateral inguinal lymph node dissection was done without any intraoperative problem. The part of the lesion in approximation with the pubic bone could be lifted after careful, patient dissection. The woman did well postoperatively. However 2 lymph nodes on left side came out to be positive for malignancy. So after wound healing chemotherapy in the form of Ifosfamide and Adriamycin (6 cycles) and Radiotherapy were given. Woman is under regular follow-up and doing well. Thus a woman who on initial examination looked inoperable could be treated adequately.

## Discussion

Invasive squamous cell carcinoma accounts for 90% of all invasive malignancies of the vulva, which are responsible for only 1-4% of all female cancers. Sarcoma is relatively uncommon. Subtypes include

leiomyosarcoma, malignant fibrous histiocytoma, and epithelioid sarcoma. Malignant fibrous histiocytoma is a painless mass that most often occurs in the extremities. The condition most commonly metastasizes to the lungs, but can also invade the lymph nodes and bone. The exact cause of malignant fibrous histiocytoma is not entirely understood, however, genetic alterations may play a role. The most conclusive diagnostic procedure for soft tissue sarcomas is a biopsy. This form of cancer is distinguished from other sarcomas by its appearance under a microscope. Bone scans are done for metastasis. Immunohistochemistry displays vimentin reactivity and negativity for keratins and leukocytic common antigen. Surgery for malignant fibrous histiocytomas involves the biopsy, surgical removal of the tumor, bone/s 89 kin grafts, and/or reconstruction. The type of surgery will depend on the size and location of the tumor, and whether the cancer has spread. Radiation damages or kills cancer cells and shrinks tumors. This is sometimes used in conjunction with surgery for malignant fibrous histiocytoma, either before or after resection of the tumor. On rare occasions radiation alone is used for treatment of the primary tumor. Chemotherapy works by interfering with the cancer cell's ability to grow or reproduce. Chemotherapy may be used alone for some types of cancer or in conjunction with other therapy such as radiation or surgery. Other treatment options for MFH under study are Angiogenesis inhibitors and Biological therapies. Angiogenesis inhibitors prevent the growth of the tumors by blocking the formation of new blood vessels that feed the tumors. The 5 year survival rate of tumors < 5 cms is 82 % for tumors 5 – 10 cms size is 68 % and those for tumors > 10 cms is 51 % . For intermediate grade tumors the 5 year survival is 80 % and 60 % for high grade tumors. In the case which presented to us surgery with chemo radiotherapy was used judiciously to manage the condition.

## Conclusion

A vulval malignancy is quite a traumatic experience in a female of any age group. More so in a 40 year old who is young and suffers a lot psychologically. The delay in seeking treatment is one of the important reasons which leads to advanced stage of the disease on presentation.

---

Thorough investigations to stage the disease correctly and decide operability is imperative. In a resource poor setting of rural India this proves to be a great challenge. A Cancer Relief Fund set aside for needy patients proves to be stress relieving and decisive as in this case. Skillful technique during dissection allows proper cytoreduction so that postoperative treatment with chemotherapy or radiotherapy becomes more effective.

## References

1. O'Brien JE, Stout AP. Malignant fibrous xanthomas. *Cancer (Philad)* 1964;17:1445-1455.
2. Yip D, MD, Scott S G, MD, Malignant Fibrous Histiocytoma, *Soft Tissue : e -medicine*, March 2008
3. Taylor RN, Bottles K, Miller TR, Braga CA. Malignant fibrous histiocytoma of the vulva. *Obstet Gynecol.* 1985 Jul;66(1):145-8.
4. Sabesan T, Xuexi W, Yongfa Q, Pingzhang T, Ilankovan V. Malignant fibrous histiocytoma: outcome of tumours in the head and neck compared with those in the trunk and extremities. *Br. J Oral Maxillofac Surg.* Jun 2006;44(3):209-12. Epub 2005, Jul 18.
5. Vural B, Ozkan S, Yildiz K, Corakçi A, Gürbüz Y. Malignant fibrous histiocytoma of the vulva: a case report. *Arch Gynecol Obstet.* 2005 Dec;273(2):122-5. Epub 2005 Jul 30. *Gynecol Oncol.*
6. Santala M, Suonio S, Syrjänen K, Uronen MT, Saarikoski S Malignant fibrous histiocytoma of the vulva. 1987 May;27(1):121-6.

