

QUIZ
[Quiz No. 4, PMR Vol. 05 (4)]
Radiology Quiz – B-Scan

Aironi V D*, Mishra S**, Gandage S G***, Jadhav M T****,

Case History

A twenty five year old male patient came for B-scan to Department of Radiology. He had history of trauma to face and orbit one year back. Now he developed proptosis with dilatation and prominence of episcleral veins on clinical examination bilaterally. Further ophthalmic examination revealed presence of bilateral glaucoma. There was presence of vascular bruit over the eyeballs with pulsatile proptosis bilaterally. A B-scan was performed on Siemens Sonline ultrasound examination with 10 MHz linear probe. The following B-scan images show the underlying condition. What is your diagnosis?

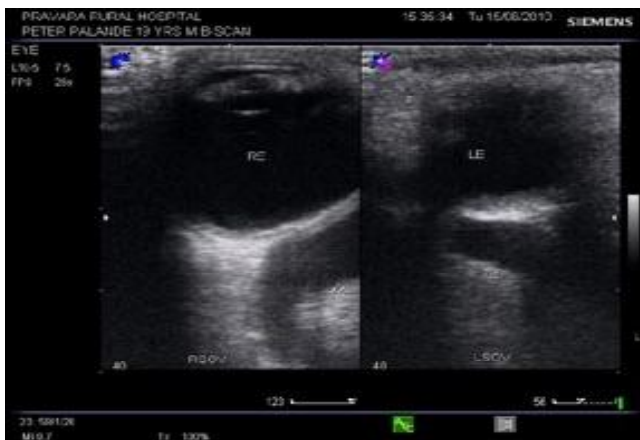

Fig 1: Grey scale ultrasound image of both orbits in axial plane

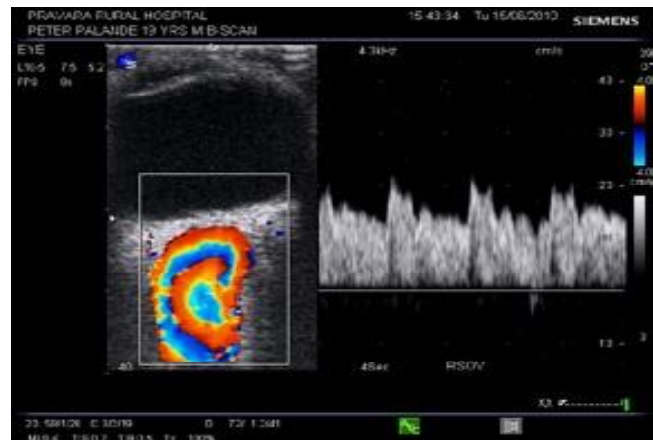


Fig 2: Colour Doppler study of right orbit with spectral waveform.

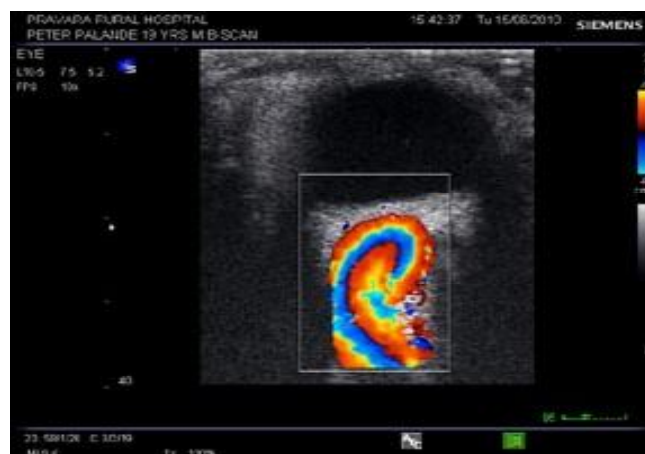

Fig 3: Colour Doppler study of left orbit

- * Associate Professor, Department of Radio-diagnosis
- ** Professor, Department of Ophthalmology
- *** Professor and Head, Department of Radio-diagnosis
- **** Postgraduate Student, Department of Radio-diagnosis