

## Hailey-Hailey Disease- A Case Report

Sangoram S S\*, Indurkar V A\*, Amin-Hon V S\*\*, Nishigandh P D\*\*

### Abstract

Forty five years old male presented with macerated, fissured patch in both axilla and groin since 15 years, treated symptomatically with waxing and waning response. History of similar complaints in father/ paternal aunt and sister. Characteristic “dilapidated brick wall appearance” due partial loss of cohesion of epidermal keratinocytes was observed histologically. The diagnosis of Hailey-Hailey disease was made, on the basis of history, clinical and histological features. Appropriate treatment was started and regular follow up was advised to evaluate the outcome.

**Keywords:** Hailey-Hailey disease, ATP2C1 Mutation, Partial Acantholysis.

### Introduction

Hailey-Hailey disease (HHD) is a rare and chronic disorder, inherited as an autosomal dominant trait. The Hailey brothers first described the condition in the year 1939.<sup>[1]</sup> Family history is obtained in about two-thirds of the patients. Incidence is 1 in 50,000 and appears in the third decade of life. It is a relatively uncommon disease in India.<sup>[2]</sup> It is clinically characterized by recurrent vesicles which rupture, leaving painful fissures (rhagades) and scaly erythematous plaques in the flexures.<sup>[3]</sup> Topical or systemic corticosteroids with antibacterial agents are effective treatments in most patients. The severity of the disease decreases with increasing age.<sup>[3]</sup>

### Case report

Forty five years old male patient, veterinary doctor by profession, presented with macerated fissured patch in both axilla and groin (Fig. 1 & 2) with limited mobility since 15 years. Onset was gradual with exacerbation during summer, was treated symptomatically with waxing and waning response. History of similar complaints in father/ paternal aunt and sister was present.

\*Registrar, Dept of Skin V.D, RMC, Loni

\*\*Resident, Dept of Skin V.D, RMC, Loni

#### Address for correspondence:

Dr. Sham Shesho Sangoram,  
Department of Skin V.D., RMC, Pravara Rural Hospital,  
Loni-413736, District- Ahmednagar, Maharashtra (India).  
E-Mail: psychiatry@pmpims.org

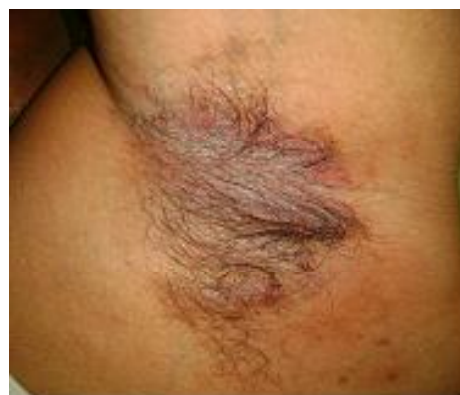

Fig 1: Macerated plaque with painful fissures of the Axilla

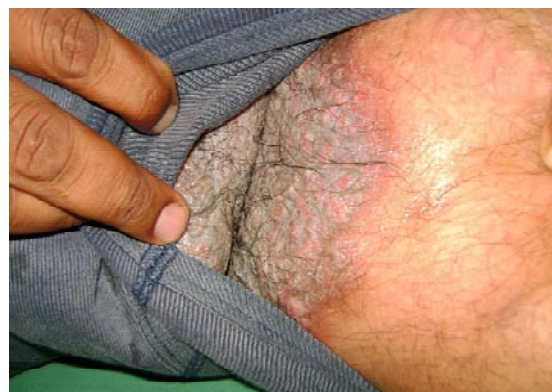

Fig.2: Macerated plaque with painful fissures of the Groin

There was no evidence of any mucous membrane involvement. Other systems were also normal. Routine investigations of blood and Chest X-ray were all within normal limits. From history and clinical presentation provisional diagnosis of Hailey-Hailey disease was made and lesional skin biopsy was taken for histopathological examination. The histopathology showed characteristic loss of cohesion between keratinocytes (acantholysis) with epidermal clefting or vesiculation. Widespread partial loss of the intercellular bridges between keratinocytes gives the epidermis the appearance of a 'dilapidated brick wall'. These features were suggestive of HHD (Fig 3).

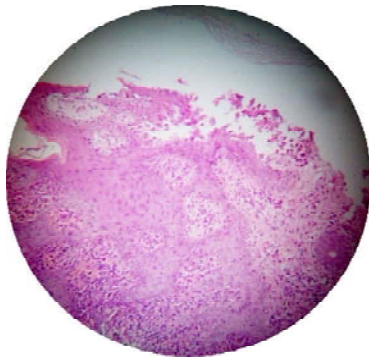


Fig 3: Shows loss of intercellular contacts within the upper layers of the epidermis giving the appearance of a "dilapidated brick wall".

Management, prognosis of the disease and proposed line of treatment was explained to the patient. He was put on low dose systemic & topical corticosteroid and supportive treatment. Regular follow up visits were explained to the patients to chart clinical improvement and also monitor side effects related to corticosteroid.

## Discussion

HHD is also called familial benign chronic pemphigus. It is thought to be caused by heterozygous mutations in the ATP2C1 gene on chromosome 3q21-q24 which encodes ATPase1. In affected individuals, reduced

activity of this enzyme might cause instability of the desmosomes which results in loss of cohesion between keratinocytes (acantholysis), and development of vesicles. Mechanism by which mutant ATP2C1 cause acantholysis is unknown.<sup>[4]</sup> The disease is more severe in summer. Flexural forms may become hypertrophic and malodorous. Mucosal involvement is rare, but oral, esophageal, vulvar and conjunctival involvement has been reported.<sup>[5]</sup> Longitudinal white lines on the fingernails can be seen and fine palmer pits have also been documented. There are no extra-cutaneous manifestations and the general health is not impaired. Inheritance: Penetrance in adults is complete but expressivity is variable between and within affected families. Two types of mosaicism are seen in HHD: Type 1: Segmental manifests as a streak or multiple localized streaks of disease along Blaschko's lines in a patient without evidence of the disorder elsewhere. Type 2: Characterized by severely affected unilateral segmental areas along Blaschko's lines superimposed on classic disease. Diagnosis is mainly based on clinical presentations, positive family history and characteristic histopathology which shows "dilapidated brick wall" appearance and negative immunofluorescent studies. Differential diagnosis includes Intertrigo, Eczema, Darier disease and Pemphigus vegetans. HHD is difficult disease to treat, and various therapeutic modalities must be considered. To help minimize friction, patient weight should be maintained at appropriate levels and comfortable clothing should be worn to prevent heat, moisture and friction. Exacerbations can be controlled with systemic antibiotics. Systemic, topical and intralesional steroids are also effective. Dapsone is used in refractory cases. Topical tacrolimus, calcipotriol, systemic and topical cyclosporine, etretinate, methotrexate have also been used. For recalcitrant lesions wide excision of the involved area with replacement by split thickness skin grafts is widely accepted.<sup>[6]</sup> Erbium: YAG (Yttrium-Aluminium-Garnet) and CO<sub>2</sub> laser ablation have also been reported to be effective.<sup>[7]</sup> HHD has a chronic fluctuating course, and

patients undergo recurrent exacerbations and remissions that can last months to years. The disease can severely affect the quality of life.<sup>[8]</sup> The development of squamous cell carcinomas on HHD skin lesions has been reported in rare cases.<sup>[9]</sup>

### Conclusion

HHD should be suspected in young adult patient with chronic recurrent vesicles/ painful fissures and scaly erythematous patch that involves flexures and not responding to routine line of treatment.

### Reference

1. Hailey H, Hailey H. Familial benign chronic pemphigus. Arch Dermatol 1939; 34: 679-85.
2. IADVL Textbook of Dermatology, Volume 1, 3<sup>rd</sup> Edition. Bhalani Publication 2008: 1127-1128.
3. Burge SM, Hailey-Heiley disease: the clinical features, response to treatment and prognosis. Br J Dermatol. 1992; 126:275-82.
4. Dhitavat J, Fairclough RJ, Hovnanian A, et al. Calcium pumps and keratinocytes: lessons from Darier's disease and Hailey-Hailey disease. Br J Dermatol. 2004; 150: 821-8.
5. Botvinick I. Familial benign pemphigus with oral mucous membrane lesions. Cutis. 1973; 12:371-373.
6. Thorne FL, Hall JH, Mladick RA. Surgical treatment of familial chronic pemphigus. Arch Dermatol. 1968; 98:522-524.
7. Beier C, Kaufmann R. Efficacy of erbium-YAG laser ablation in Darier disease and Hailey-Hailey disease. Arch Dermatol. 1999; 135:423-427.
8. Gisondi P, Sampogna F, Annessi G et al: Sever impairment of quality of life in Hailey-Hailey disease. Acta Derm Venereol 85: 132, 2005 (PMID: 15283906)
9. Hoist VA et al: Squamous cell carcinoma arising in HHD. J Am Acad Dermatol 43: 368, 2000. (PMID: 10901726)

