

## Management of a Preterm baby – The Challenges

Gopinathan Nambiar\*, R Chatterjee\*\*, D Y Shrikhande\*\*\*, Kunal Ahya\*

### Abstract

*A 32 weeks preterm baby weighing 1362gms, born in rural area was brought to Pravara Rural Hospital after significant delay and received much needed tertiary care. Survival of the baby was possible because of aggressive management of multiple complications that prematurity and low birth weight confers.*

**Key words :** *Congenital heart disease, Hyaline membrane disease, Hydrocephalus, Preterm, Septicemia*

### Introduction

A baby born before 37 completed weeks of gestation is called a preterm. About 12 percent of Indian babies are born preterm as compared to 5 percent incidence in the west, that too majority of them belong to rural areas<sup>[1]</sup>. The advances in the field of neonatology over the past 20 years have improved the survival of preterm and low birth weight babies all over the world.

The functional immaturity of various systems result in different clinical problems like hypothermia, hypoglycemia, hyperbilirubinemia, birth asphyxia, immaturity of lungs with hyaline membrane disease, recurrent apnea, life threatening infections, intraventricular hemorrhages, congenital heart diseases etc. We often come across preterm babies with some of these handicaps, but it is uncommon to see a baby who has survived after battling all the multiple morbidities mentioned above and more.

### Case Report

A preterm male baby, 32 weeks of gestation weighing 1362 gms was born to a primi gravida mother with

\* Resident, Dept of Paediatrics, Rural Medical College, Loni

\*\* Professor, Dept of Paediatrics, Rural Medical College, Loni

\*\*\* Professor & Head, Dept of Paediatrics, Rural Medical College, Loni

#### Address for correspondence:

Dr. Gopinathan Nambiar  
Department of Pediatrics  
Rural Medical College  
Pravara Institute of Medical Sciences  
At post: Loni, Taluka – Rahata, Dist – Ahmednagar-Pin:413736  
ggnambiar@gmail.com

history of premature rupture of membrane (PROM) for 19 hrs at a private hospital in rural area. There the Obstetricians suspected intra uterine death as no fetal heart sound was heard by them. However on delivery the baby was asphyxiated and cried after 10 minutes. The baby was referred for intensive care to Pravara rural hospital, where he reached at 5hrs of age and was admitted in NICU. On admission baby was cold, sick looking, tachypnoeic, cyanosed, along with audible grunt. The baby was nursed in open care system under the radiant warmer. On examination chest retractions, nasal flaring and poor air entry in both lungs were noted. Chest x-ray showed ‘ground glass’ appearance (Fig. 1). Diagnosis of Hyaline Membrane Disease (HMD) was made. Exogenous natural surfactant (Survanta, 4ml/kg) was administered intratracheally by INSURE (i.e., intubation, surfactant administration and extubation) method followed by continuous positive airway pressure ventilation (CPAP) at 6 cm H<sub>2</sub>O initially and was reduced to 5 cm H<sub>2</sub>O later when the retractions improved. After 72 hrs, baby was weaned off to O<sub>2</sub> by hood box. The very low birth weight neonate was started on phototherapy for hyperbilirubinemia<sup>[2]</sup>. On 3<sup>rd</sup> day of life baby showed features suggestive of septicemia manifesting as fever, lethargy and brown aspirate from stomach, inspite of antibiotic therapy (cefotaxime 50mg/kg iv 12hrly, amikacin 7.5mg/kg iv 12 hourly) since admission. He showed progression of sepsis as he developed sclerema, which first appeared on the legs and started progressing towards

the chest. Baby also had a seizure for which he was put on phenobarbitone. Lumbar puncture done was suggestive of meningitis. Antibiotics were stepped up (meropenem 20mg/kg iv 12hrly, vancomycin 15mg/kg iv 12hrly) along with appropriate supportive care. On 5<sup>th</sup> day of life the baby had apnoea. On examination child had severe pallor and persistent bradycardia. The lumbar puncture was repeated and it was uniformly blood stained with 3 vial test positive. The diagnosis of intraventricular hemorrhage was made and blood transfusion was given immediately. Baby was put on ventilator with apnoea settings. Serial lumbar punctures over the next week were done till clear fluid without blood stain came. The baby's general condition started improving by ninth day of life and was weaned from the ventilator. Baby was shifted to step down neonatal care in SCNU and thereafter to mother for Kangaroo Mother Care (KMC). Expressed breast milk was given through nasogastric tube initially. Gradually within 1 week baby started accepting breast feeds. Head circumference was monitored weekly which showed a gradual increase. Subsequent neurosonography done showed dilated lateral and third ventricles suggestive of aqueductal stenosis(Fig.3). Acetazolamide was given orally and antibiotics were continued for 21 days. CT Head confirmed the diagnosis of non communicating hydrocephalus.

On echocardiography, ostium secundum type of atrial septal defect (ASD) was detected for which the parents were advised to be on follow up till baby gains weight and subsequent closure can be planned.

## Discussion

The present case shows that the survival of preterm baby with acceptable morbidities is possible in a teaching hospital in rural India, with facilities for advanced neonatal care. Such cases are a stimulant to serve the underprivileged in remote and far flung areas. The baby was born as a preterm due to premature rupture of membranes and had perinatal asphyxia in addition. Respiratory distress due to immaturity of lungs (HMD) was manifested in early hours of life.<sup>[3]</sup> Surfactant therapy using INSURE technique increased the functional residual capacity of his lungs to restore

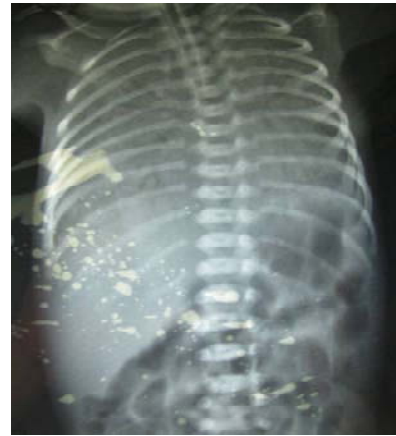

Fig.1: X-Ray chest-showing ground glass appearance of both lung fields before surfactant therapy

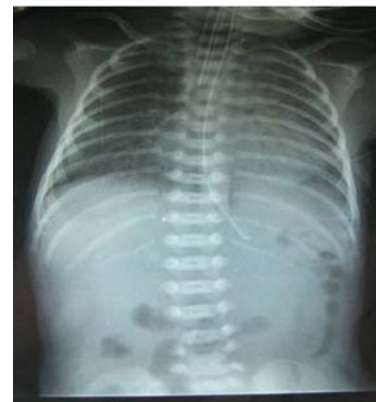

Fig.2:X-Ray chest-showing Clearance of lung fields after surfactant therapy

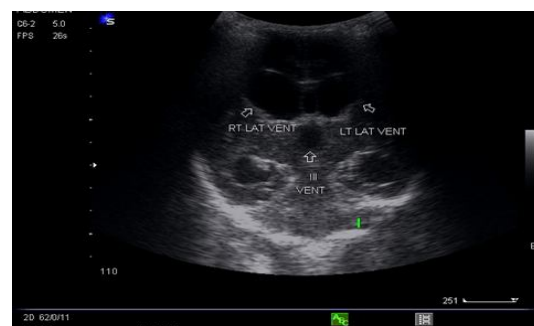


Fig.3: Neurosonography showing dilated lateral ventricles and IIIrd ventricle suggestive of aqueductal stenosis

compromised respiration(Fig 2).<sup>[4,5]</sup> Risk factors for septicemia were high and child developed early onset septicemia which was managed with appropriate antibiotics.<sup>[6]</sup> But appearance of sclerema, the uniform hardening of the skin, was another sign of grave prognosis.

Early detection and aggressive management of sepsis showed excellent results. Baby developed meningitis followed by intraventricular haemorrhage and resultant hydrocephalus.<sup>[7]</sup> In addition to treatment of meningitis, intraventricular haemorrhage was managed by repeated therapeutic lumbar punctures till CSF cleared.<sup>[8]</sup> Measures to reduce raised intracranial pressure included oral acetazolamide,<sup>[9]</sup> fluid restriction and adequate oxygenation. Further increase in head size will define the need for intervention, i.e., ventricular peritoneal shunt. Atrial septal defect requires closure, later on after baby had gained weight and maturity.<sup>[10, 11]</sup> Early intervention therapy with sensori-motor stimulation and milestone developmental activities is known to reduce the adverse developmental impact of multiple morbidities in such children.<sup>[12]</sup>

Present condition of the infant shows partial neurodevelopmental delay. Baby had achieved developmental milestones of 2 months of age, at the age of 5 months. He has no visual or hearing handicaps, has good eye contact and eye fixation, cognitive milestones of social smile, cooing vocalization sounds have been achieved. Parents are regularly bringing the baby to the high risk neonatal follow up clinic in the Pediatric department. He is also being seen by early interventionist and special educator at college of Physiotherapy of Pravara Institute of Medical Sciences. The multidisciplinary approach being implemented is likely to result in better sensori-motor as well as cognitive improvement and a future of a little brighter hue.

## Conclusion

Helping the sick tiny neonates to fight for their life in NICU and during step down in SCNU before transferring to supervised maternal care in growing nursery, demands the highest levels of commitment. The awareness that the sick newborn is an individual in need of special care will enhance the development of advanced neonatal intensive care system in developing

countries thereby improving both survival and quality of life.

## References

1. Meharban Singh. Care of the Newborn, Sixth Edition, 2004. 17, 219.
2. Gartner L.M: Disorders of bilirubin metabolism. In Nathan D.G,Oski F.A(eds):Hematology of infancy and childhood,3<sup>rd</sup> edition Philadelphia, W.B.Saunders company,1987,P-92
3. Warren, J. B., Anderson J. M. (2009) care concepts : Respiratory distress syndrome, neoreviews 10 : e351 – e361
4. H.L. Halliday surfactants: past, present and future Journal of Perinatology (2008) 28, 547 – 556; doi 10. 1058/jp 2008. 50
5. Bohin K, Gudmundsdattiv T, Katz – Salamon M, et al. Implementation of surfactant treatment during continuous positive airway pressure, Journal of Perinatology (July 2007); 27 : 422 – 427
6. Shankar MJ, Agarwal R, Deorari AK, Paul VK. Sepsis in the newborn Indian J Pediatr. 2008 Mar;75(3) :261-6
7. Anwar M, Kadam S, Itialt I. M, Hegyit, Serial lumbar punctures , intervention of post hemorrhagic hydrocephalus in preterm infants, Journal of Pediatrics 1985; 107 . 446 – 456
8. Dykes FD, DunbarB, Lazarra A, Ahmann PA, post hemorrhagic hydrocephalus in high risk infants, natural history, management and long term outcome, Journal of Pediatrics 1989; 114 : 611 – 8
9. Kliegman, Behrman, Jenson, Stanton. ‘Nelson textbook of pediatrics’. 18<sup>th</sup> edition, Medications. P-2955
10. Flanagan MF, Taylor DC. “Cardiac Disease”. In Avery GB, Fletcher MA, MacDonald MC, eds. *Neonatology*. Philadelphia: J.B. Lippincott. 1994:519.
11. Anita Saxena “Consensus on timing of intervention for common congenital heart diseases” Indian Pediatrics vol.45.117-125.2008
12. MJ Guralnick - The effectiveness of early intervention – 1997, 119 – 128