

## Efficacy of fixed twin block : A clinical and cephalometric study

Mote NR\*, Toshniwal NG\*\*

### Abstract

*The major problem with removable functional appliance is that a large amount of patient co-operation is required. The efficacy of the removable Twin Block (RTB) appliance (and its modifications) has already been proved by many workers. A major drawback of this appliance is patient compliance, therefore, the aim of this study was to evaluate the effectiveness of a fixed twin block appliance (bonded type) in subjects who reported during the last phases of skeletal growth with a Class II skeletal pattern. A six month cross-sectional prospective cohort study was conducted with a sample size of 20 subjects (9 males and 11 females). Evaluation of the changes in the profile view using clinical and cephalometrical findings were carried out. Appliance was found to be effective and useful for correction of retropositioned lower jaw, specially during the circumpubertal growth spurts in both sexes.*

**Key words:** malocclusion, last phase growth spurts, circumpubertal, retroposition, cephalometric.

### Introduction

It is a well documented fact that most common skeletal class II malocclusions are due to the retrognathic and / retro-positioned lower jaw.<sup>[1]</sup>

Amongst the Functional Jaw Orthopaedic (FJO) series, the Twin block appliance (TBA) received worldwide popularity after its introduction by W.Clark in 1977 due to increased compliance, efficacy and the advantages it offers over other such appliances in correcting such defects.<sup>[2]</sup> Despite this, the compliance rate with TBA is still not as good as compared to Fixed functional appliances (FFA).<sup>[3]</sup> Hence, an effort has been made in this study to search for appliance philosophy which will not only be 100% compliant and cost effective but less time consuming (fabrication + placement) as well, and will also elicit prompt response in those cases where dental arches are well aligned. The appliance was designed keeping in view all ideal requirements of fixed functional appliances endorsed by De Vincenzo in 1997.<sup>[4]</sup>

### Aims and Objectives

1. To evaluate changes produced by fixed twin block appliance clinically with the help of change in amount of overjet, molar relation and canine relationship (from Angle's class II to class I relation).
2. To evaluate the treatment effect of fixed twin block on mandibular growth by cephalometric methods.

### Material and Methods

- A) A six month cross sectional prospective cohort study was conducted with a sample of 20 subjects (9 males and 11 females) with the mean age of 13.8 years (S.D±1.4 years). The following selection criteria were followed before including the subjects in the study group:
1. Brachycephalic facial type with convex facial profile.
  2. Clinically, bilateral Angle's Class II Division 1 malocclusion.
  3. Well aligned individual dental arches.
  4. Clinical Visual treatment objective (VTO) was positive.<sup>[5]</sup>
  5. No transverse skeletal as well as dental maxillary arch discrepancy.
  6. Last phase of skeletal growth spurts. (As per Fishman's skeletal maturity indicators

\*Assistant Professor, \*\*Professor and Head.  
Department of Orthodontics, Rural Dental College, Loni.

### Address for correspondence:

Dr. Nilesh Mote,  
Assistant Professor, Department of Orthodontics, Rural Dental College,  
Loni, Tal. Rahata, Dist. Ahmednagar, Maharashtra, India.-413736  
Email: drnileshmote@yahoo.co.in

(S.M.I.).<sup>[6]</sup> S.M.I. 9 or 10 but not completed the S.M.I. 11. Stage 4 or stage 5 of Cervical Vertebrae Maturity Indices (CVMI).<sup>[7]</sup>

7. Cephalometrically skeletal class II i.e. increased Angle ANB (5-8 degrees) with orthognathic maxilla and retrognathic mandible and favourable growth pattern.
8. No history of orthodontic treatment.
9. No symptoms of temporomandibular joint disorder, neuromuscular, auditory and mandibular dysfunction syndrome.

### B) Fabrication of appliance

Appliance mainly consists of following two components:

1. Maxillary wire framework with inclined biteblocks (Acrylic).
2. Mandibular wire framework with inclined biteblocks (Acrylic). Detailed steps of fabrication of fixed twin block appliance is as follows.

#### 1) Maxillary wire component (Fig. 1)

The maxillary framework mainly consisted of three components:

- a) Two wire frameworks, one on each side of quadrant made up of 19 gauge stainless steel (SS).

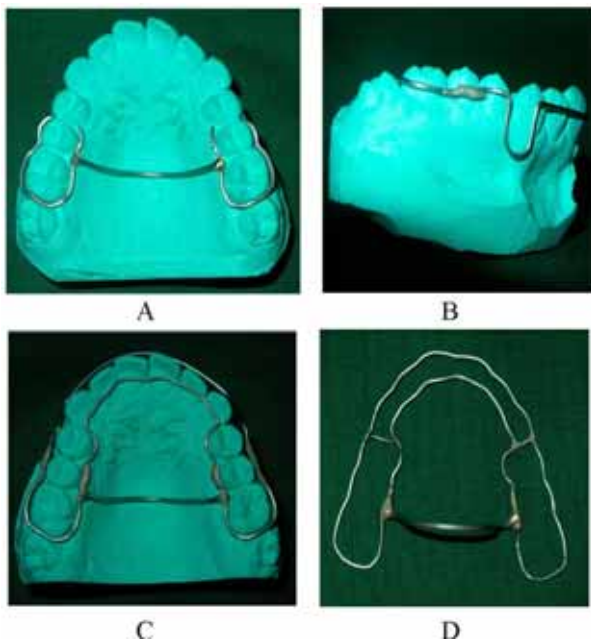


Figure 1: Maxillary wire component

- b) A rigid transpalatal bar crossing the palate made up of 18 gauge stainless steel to provide cross arch stability to appliance.
- c) A labial bow (fitted or with loop).
- d) Palatal bow in 21 gauge stainless steel.

A small wire component running buccolingually just distal to canine was adapted in the occlusal embrasure and soldered to fitted labial bow on the buccal side and the palatal bow on palatal side for vertical stability.

The entire small wire components were soldered to each other as shown in figure (fig 1) to form the maxillary wire framework.

#### 2) Mandibular component wire framework

The mandibular wire framework mainly consisted of two wire components

- a) A labial bow with 'U' loop incorporated around the distal one third of canine.
- b) A lower lingual bar, closely adapted to the lingual surface of the anteriors immediately above the cingulum of lower anterior teeth.

This labial extension was then soldered to the distal extension of the labial bow around the first bicuspid area.

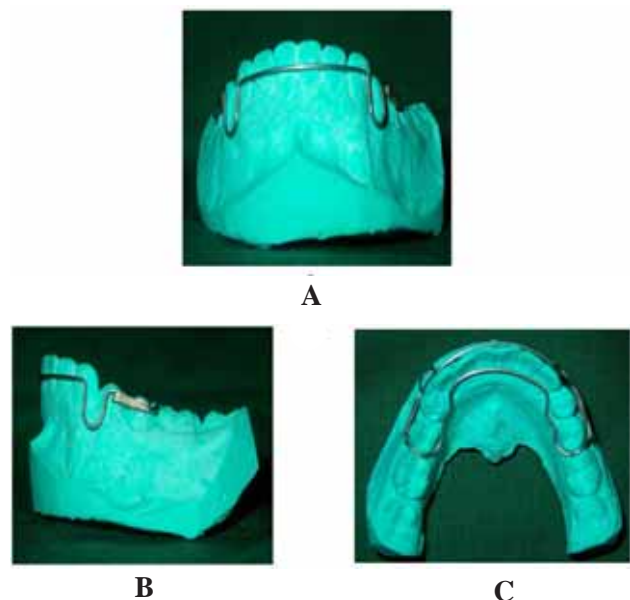


Figure 2 : Mandibular wire component

#### C) Acrylization of the appliance:

The basic philosophy of upper and lower inclined occlusal blocks was the same for this modified version as that of the removable one.

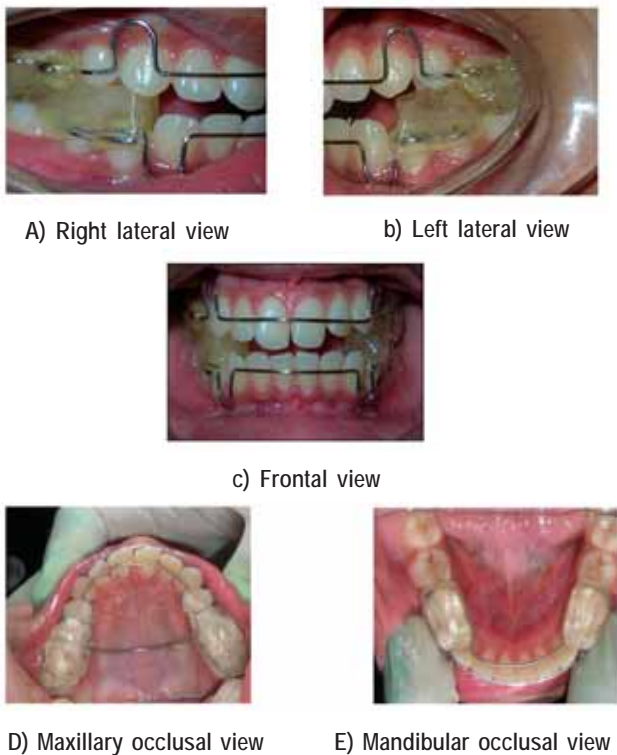


Figure 3 : Intraoral photographs of the fixed twin block appliance in place

**D) Bite registration**

The necessary protocol for recording the construction bite for retropositioned lower jaw was followed for each subject.<sup>[8]</sup>

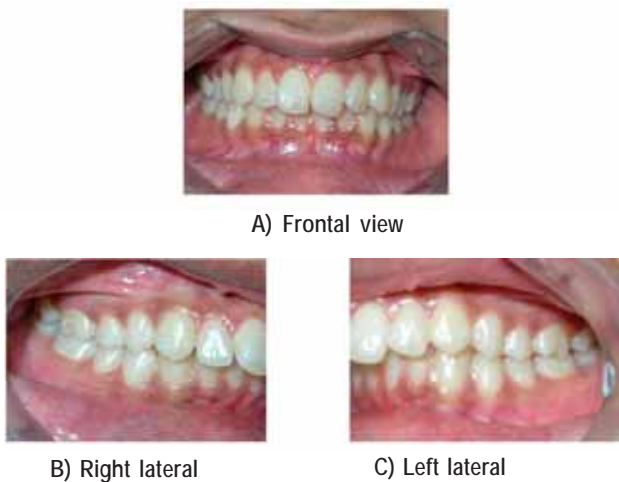


Figure 4 : Pretreatment intraoral photographs

**E) Placement (Cementation) of appliance:**

After mouth scaling and polishing, the fluoride application was carried out. The upper and lower

components of the fixed twin block were cemented with luting type of Glass Polyalkenoate cement.

All the necessary instructions regarding feeling of initial discomfort, pain, difficulty in speech and eating was imparted to the patients and their parents.

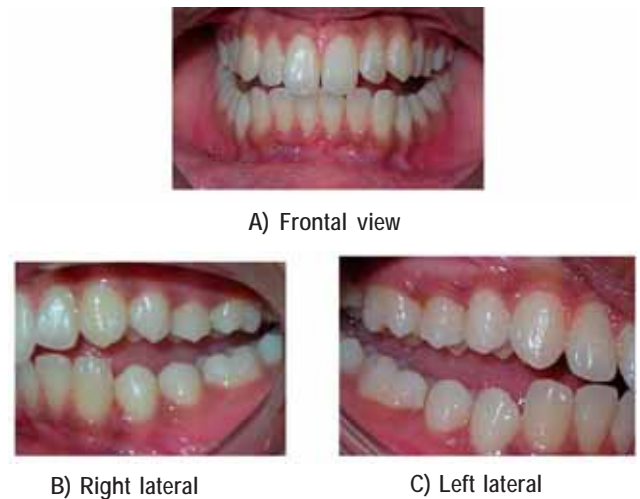


Figure 5 : Post-treatment intraoral photographs

**Results and Statistics**

Clinical and cephalometrical pre and post-treatment changes during a six month period was analysed by applying the student's unpaired 't' test.

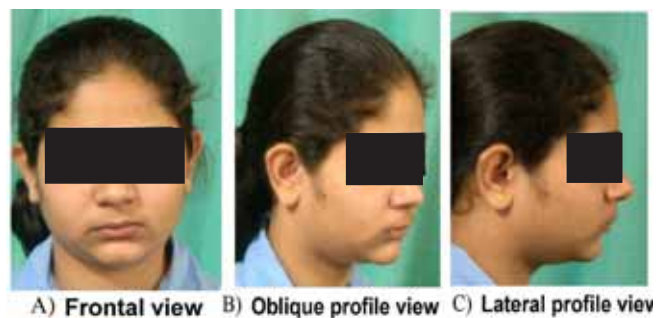


Figure 6 : Pretreatment extraoral photographs

**Clinical evaluation (Table 1)**

1. The initial mean pretreatment value of overjet and overbite was  $(8.75 \pm 0.94)$  and  $(5.05 \pm 0.74)$  respectively, which at the end of the study duration decreased to  $(3.17 \pm 1.02)$  and  $(2.16 \pm 0.69)$  respectively. This decrease was statistically highly significant ( $p < 0.01$ ).

- The linear distance of both molar and canine of right and left side decreased (indicative of shift from class II to class I relation) during study duration. This decrease was also statistically highly significant ( $p < 0.01$ ).

**Table 1:** Comparison between mean values of linear change in molar and canine relationship and change in Overjet and Overbite before and after treatment with fixed twin block appliance (n=20):

|                    | Pre-treatment (n=20)<br>Mean±SD | Post-treatment (n=20)<br>Mean±SD | t value | p value | Result             |
|--------------------|---------------------------------|----------------------------------|---------|---------|--------------------|
| Overjet            | 8.75±0.94                       | 3.17±1.02                        | 18.0    | p<0.01  | Highly significant |
| Overbite           | 5.05±0.74                       | 2.16±0.69                        | 12.04   | p<0.01  | Highly significant |
| Molar Relation Rt  | 4.17±0.96                       | 1.55±0.12                        | 21.84   | p<0.01  | Highly significant |
| Molar Relation Lt  | 4.65±0.84                       | 2.24±1.62                        | 14.25   | p<0.01  | Highly significant |
| Canine Relation Lt | 4.82±1.34                       | 1.0±0.84                         | 18.69   | p<0.01  | Highly significant |
| Canine Relation Lt | 4.90±0.66                       | 0.84±0.19                        | 22.53   | p<0.01  | Highly significant |

**Cephalometrical evaluation (Table 2)**

- The mean value of post-treatment angle SNA (79.86±2.32) was more or less same as that of the mean pretreatment value of angle SNA (80.15±2.35°) with statistically nonsignificant difference ( $p > 0.05$ ).
- The mean value of post-treatment angle SNB (79.10+2.57°) was significantly greater than the mean value of pretreatment angle SNB (74.5°+2.5°) ( $p < 0.01$ ).
- It was therefore concluded that there was statistically significant difference between pre and post-treatment angle SNB, thereby indicating change in sagittal position of the lower jaw (reduced ANB).
- The other pre and post-treatment cephalometric parameters were also assessed by using the same test. Mean values of the rest of the post treatment cephalometric parameters were: (<ANB - 0.38±0.14, <SN(selion - nasion) – Pog(pogonoin)- 82.54±2.38, Co-Gn (condylion-gnathion)- 112.27±4.43mm, GoGn (gonion-gnathion)- 74.5±2.89°, Art-Go (articular - gonion) - 46.12±3.32, Co-Go (condylion- gonion) 55.07±1.95). They were significantly higher than

respective pretreatment cephalometric parameters except for < ANB, which was significantly lower than the pretreatment cephalometric parameter. (<ANB-5.5±0.87, <SN - Pog -76.5 ±2.64, Co-Gn-105.35± 4.59mm, GoGn - 71.64 ± 2.76mm, Art-Go-44.53±1.89mm, Co-Go-51.56±1.86mm). Thereby concluding that there exists a statistically significant difference between pre and post-treatment cephalometric parameters.

**Table 2 :** Comparison between mean values of cephalometric analysis in pretreatment and post treatment group:

|         | Pre-treatment (n=20)<br>Mean±SD | Post-treatment (n=20)<br>Mean±SD | t Value | p value | Result             |
|---------|---------------------------------|----------------------------------|---------|---------|--------------------|
| <SNA    | 80.15±2.35                      | 79.86±2.32                       | 0.39    | p>0.05  | Not significant    |
| <ANB    | 5.5±0.87                        | 0.38±0.14                        | 42.66   | p<0.01  | Highly significant |
| <SN-Pog | 76.5±2.64                       | 82.54±2.38                       | 11.84   | p<0.01  | Highly significant |
| Co-Gn   | 105.35±4.59                     | 112.27±4.43                      | 5.72    | p<0.01  | Highly significant |
| Go-Gn   | 71.64±2.76                      | 74.5±2.89                        | 3.21    | p<0.01  | Highly significant |
| Art-Go  | 44.53±1.89                      | 46.12±3.32                       | 6.27    | p<0.01  | Highly significant |
| Co-Go   | 51.56±1.86                      | 55.07±1.95                       | 6.75    | p<0.01  | Highly significant |
| NaMe    | 111.6±7.02                      | 116.63±5.59                      | 2.58    | p<0.05  | Significant        |
| I-toSn  | 113.3±5.99                      | 111.5±3.98                       | 1.12    | p>0.05  | Not significant    |
| IMPA    | 101.61±3.29                     | 104.88±3.96                      | 2.56    | p<0.05  | Significant        |

To assess a headgear effect or restrain of maxillary growth, the difference in maxillary unit length (Co-A) PtA-N perpendicular and Pns-PtA (posterior nasal spine-point A) were evaluated.

The mean value of pretreatment CO- Pt A, PtA-Nper and Pns-PtA was 90.53±3.2, 1.29 ±0.39 and 49.87 ± 1.62 respectively the mean value of posttreatment maxillary unit length (Co-A) PtA-Nper and Pns-PtA was 89.88 ±3.25, 1.16 ±0.41 and 49.06 ± 1.93 respectively. There was not much difference between the pre and post-treatment maxillary unit length. The result of all this analysis was statistically not significant ( $P > 0.05$ ).

To assess the dentoalveolar change, the mean values of upper incisor to SN and lower incisor to Go-Gn were taken and subjected to unpaired “t” test.

The post treatment upper incisor to SN was 111.5± 3.98 which was not as much significantly lesser than the pretreatment to SN 113.3 ± 5.99. So there is no



statistically significant change in the upper incisor inclination ( $p > 0.05$ ).

The mean values of post treatment lower incisor to Go-Gn ( $104.88 \pm 3.96$ ) was significantly more than the mean values of pretreatment ( $101.61 \pm 3.29$ ) ( $p < 0.05$ ), thereby suggesting a statistically significant change in the dentoalveolar parameters.

## Discussion

This fixed twin block appliance fulfills all the eleven ideal requirements of fixed functional appliances given by Dr. De Vincenzo in 1997.<sup>[4]</sup>

1. Ability to function without the need for patient cooperation.
2. Aesthetic acceptability to patients.
3. Resistance to breakage.
4. Avoidance of tissue irritation.
5. Ability to produce rapid movement.
6. Promotion of good oral hygiene.
7. Functional acceptability to patients.
8. Ease of installation.
9. Low cost.
10. Minimal inventory requirement.
11. Optimal direction of force.

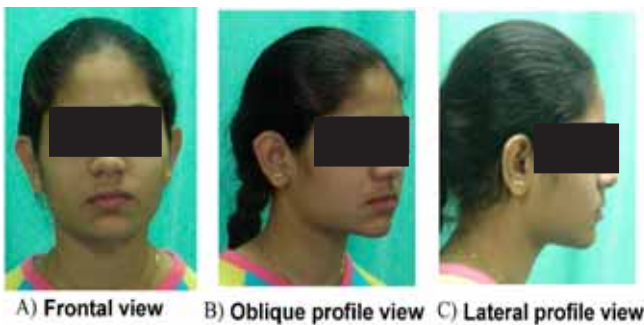

Figure 7: Post-treatment extraoral photographs

## Disadvantages

Despite the above advantages there are certain disadvantages of the appliance:

1. It cannot be used in class II div. two cases where prefunctional therapy is desired.
2. It cannot be used in late mixed dentition or early permanent dentition as this is a tooth borne appliance.
3. May results in posterior open bite
- 4 Requires long term supportive treatment to retain acquired changes.

5. It is difficult to use in an arrow maxillary arch and in anterior crowding.
6. It cannot be used in patients, having increased caries susceptibility or poor oral hygiene.

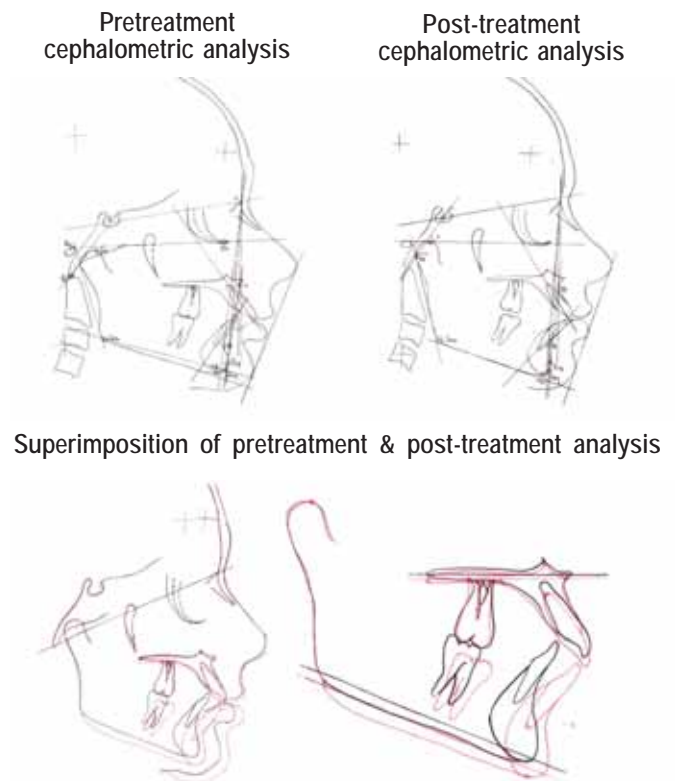


Figure 8 : Pre and Post-functional cephalometric superimposition

## Conclusion

It is difficult to compare the efficacy of this appliance with the other removable and fixed functional appliances. The most important relevant clinical feature of use of this appliance was the rate of completion of treatment without depending on compliance of the patient. More importantly we could reduce the total number of visits of patient to a minimum.

This modified version of twin block appliance has advantages such as :

1. High compliance.
2. It is effective in terms of the morphologic effects on both dental and skeletal tissues and hard and soft tissues.
3. Suits the Indian scenario.

## References

1. McNamara JA Jr. Components of Class-II malocclusion in children 8-10 years of age. *Angle Orthod* 1981; 51: 177-202.
2. Clark W.J. *Twin Block Functional therapy: Applications in Dentofacial Orthopedics*. Mosby 1995.
3. Kevin O Brien, Jean Wright, Frances Conboy, Yeweng Sanjie, Nicky Mandall. Effectiveness of early orthodontic treatment with the Twin Block appliance: A multicenter randomized controlled trial: Skeletal and dental effects. *Am J Orthod Dentofac Orthop* 2003; 124(3): 234-243.
4. DeVincenzo JP. The Eureka Spring: A new interarch force delivery system. *J Clin Orthod* 1997; 31:454-467.
5. Ricketts R.M. et.al. (1979): *Bioprogressive therapy*. Denver, Rocky Mountain orthodontics.
6. Leonard S. Fishman: Radiographic evaluation of skeletal maturity. *Angle Orthodontics* 1982; 88-112.
7. Hassel and Farman: Skeletal maturation evaluation; *Am J Orthod Dentofac Orthop* 1987: 58-66
8. William J. Clark: *Twin Block Functional Therapy- Application in Dentofacial Orthopedics: Second edition*, 2002.

