

## Various Incision Designs in Implant Dentistry

Bhandari AJ\*, Niras SR\*\*, Gangadhar SA\*\*\*

### Introduction

Surgical procedures are always filled with problem of cutting and hence damaging healthy soft tissue in order to gain access to the area of interest. While the access requirements have not changed over time, the incision techniques have changed e.g. laser, electrosurgical knife, water scalpel and piezosurgery. Irrespective of the applied technique, the surgical access must provide for[1] :

- 1) Optimal visualization of the key area
- 2) Problem-free expansion of the soft tissue
- 3) Mobilization of the overlying soft tissue to cover the surgical field
- 4) No placement over bony defects or cavities
- 5) Sufficient vascularization of soft tissue
- 6) Minimum tissue damage
- 7) Assured wound healing
- 8) Minimum esthetic impairment and
- 9) Good tissue covering.
- 10) Protecting vital organs and tissues not to damage nerves, blood vessels.

Mucosal closure has to protect the bone, the implant or the augmentation material, to establish a connection to the local supply systems as soon as possible, and to avoid infections or dehiscences. The consequences of any incision must always be kept in mind. Unlike embryological wound healing, where scarless healing is possible[2], any planned incision or injury of the covering soft tissue after birth will result in scarring which differs from regular skin or mucosa in terms of esthetics, functioning or nutrition and may be a weak point in the future.

Among many factors, vascularization has proved to be decisive for any kind of tissue regeneration. Growth,

maturation or reconstruction of the body are conceivable only with unimpaired vascularization. A knowledge of the course and supply area of the arteries is the basis for selection of the appropriate incision.

### Vascular supply of the maxilla

In the posterior part of maxilla the vestibular gingiva is supplied by branches of the infraorbital artery, and palatal mucosa by branches of descending palatine artery. Anteriorly, in the area of the premaxilla, supply is from facial artery in the vestibular parts and partially from infraorbital artery. In 66% palatal parts are supported by the descending palatine artery and in 33% by the anterior superior alveolar artery.

### Vascular supply of the mandible

The posterior lateral part of the alveolar ridge is supplied by facial artery, and anterior part by inferior labial artery and in 50% additionally by mental artery. In 73% of cases the lingual mucosa is supported exclusively by submental artery and in 27% additionally by sublingual artery. Regarding the lingual supply there is overlapping of both sides, and it was found in 20% of the cases in the vestibular part covered by facial artery.

### Recommendations for the incision (Fig.3)

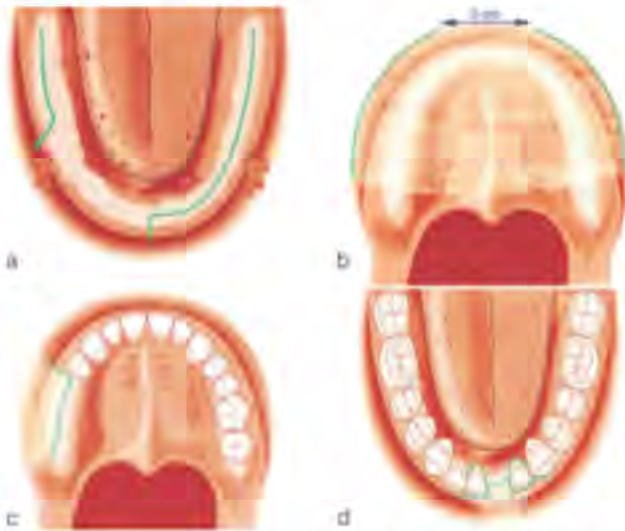
Because of divergent dentitions and, esthetic zones, as well as different parts of the gingiva (marginal, propria, mucosa) it is necessary to define and distinguish different parts of the incision line. The three decisive areas are

- The crestal part of the edentulous region,
- The bordering papilla in cases of partially dentated jaws,
- The area of the releasing incision at the anterior and posterior limit of the incision.

The midcrestal incision seems to be the ideal choice for the edentulous area of the planned implantation. Making the cut in the area of the avascular zone prevents the risk of cutting through anastomoses or cutting out avascular areas of the mucosa.

\*Professor \*\*PG Students \*\*Principal

Department of Prosthodontics, Rural Dental College  
Loni, Tal. Rahata, District-Ahmednagar, Maharashtra 413736.,



**Fig.3. Recommendations for the incision (a) edentulous areas, (b) edentulous areas: tunnelling preparation, (c) free-end situation and (d) single tooth gap.**

For esthetic reasons, only marginal incisions should be used in frontal region. Releasing incisions in the vestibule should be avoided because they will cut obliquely through defined esthetic zones and not at their borders. Releasing incisions should be carried out, if at all, only at the anterior border of incision line to avoid cutting through the vessels coming from posterior to anterior. Trapezoid flaps with anterior and posterior releasing incisions are avoidable in most cases because surgical field can be adequately visualized, and mobilization using incising of the periosteum can be achieved by anterior incision only. If it is essential not to touch marginal mucosa, an incision in the vestibulum parallel to the alveolar ridge with tunneling preparation is recommended. The papilla will be included in the incision in anterior maxilla and reconstructed using microsurgical techniques during preparation and wound closure. In lateral or posterior segment or in the event of a single posterior tooth in a free end situation the papilla can be left untouched by making releasing incision in front of the papilla.

### Discussion

In a difficult situation, the focus is on criteria relating to plastic reconstruction (e.g. preparation and mobilization of local flaps for coverage or reconstruction purposes). Most flap preparation limitations are because of inadequacy of the supporting vascular system. Esthetic aspects play a decisive role, especially in the anterior part of the maxilla. It is essential to make an incision only at the border of esthetic zones or areas and to avoid

damaging, displacement or reducing local tissue, because any substitute tissue is distinctive in its color, consistency, and surface texture.

Among all planning principles, the vascular-nutritive principle seems to be the most important one. The vascular system at the margin of a wound represents the most important nutritional structure for survival and the basis for reliable wound healing and therefore must not be damaged under any circumstances[3,4].

Consideration of the vessels involved in any soft tissue incision should be based on the extent and boundaries of the areas of supply of single major vessels. The anatomic principle of the vascular territories is referred to in the literature under the term 'angiosomes' [5,6]. Evaluations of the vascularization of specific areas of the oral mucosa have also been carried out but only few studies have referred to total assessment and a subdivision into angiosomes.

The midcrestal incision in the edentulous area of the alveolar ridge seems to be indisputably the safest and most reliable method. Incisions, which will repeatedly cross the alveolar ridge will create small mucosal areas with uncertain vascularization, leading to disturbed wound healing, bone resorption and mucosal necrosis.

If the covering soft tissue has to be extended, e.g., in cases of lateral or vertical augmentation, this can be achieved with a periosteal incision and broad undermining mobilization.

The incision of the papilla adjacent to the edentulous area is controversially debated. Reports of shrinkage and loss of interproximal bone have led to recommendations for parapapillary incisions (line angle to line angle)[7, 8]. These alternatives, designed for primary preserving of the papilla, will not allow unrestricted visualization of the lateral marginal bone and the adjacent tooth. In the event of augmentation, lateral mobilization of the gingiva is almost impossible.

The marginal incision including the papilla allows a complete overview of entire edentulous alveolar ridge and exact placement of the implant equidistant from the neighboring teeth. This incision is recommended especially for esthetically problematic areas in the upper incisor region[9,10]. Using microsurgical techniques for preparation of flaps and reconstruction of the papilla, shrinkage can be avoided when the underlying alveolar bone is not reduced and the contact point of the prosthodontic treatment is not too far from the alveolar bone[11].

From angiologic aspects the papilla is different from the adjacent edentulous alveolar mucosa because the papilla is supplied by vascular anastomoses crossing the alveolar ridge. This key point allows different incisions including or excluding the papilla. The decision has to be made individually, with aspects of esthetics and plastic reconstruction being taken into account.

## References

- 1) Johannes Kleinheinz, Andre Buchter et al. Incision design in implant dentistry based on vascularization of the mucosa. *Clin. Oral Impl. Res.* 2005, 16: 518–523.
- 2) Gary, H.G. & Longaker, M.T. *Scarless Wound Healing*. New York: Dekker. 2000
- 3) Arnold, F. & West, D. Angiogenesis in wound healing. *Pharmacology and Therapeutics*. 1991, 52: 407–422.
- 4) Endrich, B. & Menger, M.D. Regeneration der Mikrozirkulation während der Wundheilung? *Unfallchirurg*. 2000, 103: 1006–1008.
- 5) Taylor, G.I. & Palmer, J.H. The vascular territories (angiosomes) of the body: experimental study and clinical applications. *British Journal of Plastic Surgery*. 1987, 40: 113–141.
- 6) Houseman, N.D., Taylor, G.I. & Pan, W.R. The angiosomes of the head and neck: anatomic study and clinical applications. *Plastic and Reconstructive Surgery*. 2000, 105: 2287–2313.
- 7) Gomez-Roman, G. Influence of flap design on peri-implant interproximal crestal bone loss around single-tooth implants. *International Journal of Oral & Maxillofacial Implants*. 2000, 16: 61–67.
- 8) Velvart, P. Papilla base incision: a new approach to recession free healing of the interdental papilla after endodontic surgery. *International Endodontic Journal*. 2002, 35: 453–460.
- 9) Wachtel, H., Schenk, G., Bohm, S., Wenig, D., Zuhr, O. & Hurzeler, M.B. Microsurgical access flap and enamel matrix derivative for the treatment of periodontal intrabony defects: a controlled clinical study. *Journal of Clinical Periodontology*. 2003, 30: 496–504.
- 10) Erpenstein, H., Rasperini, G. & Silvestri, M. Lappenoperationen. In: Erpenstein, H. & Diedrich, P., eds. *Atlas der Parodontalchirurgie*. 1st edition, 111. München: Elsevier Urban & Fischer. 2004.
11. Tarnow, D.T., Elian, N., Fletcher, P., Froum, S., Magner, A., Cho, S.C., Salama, M., Salama, H. & Garber, D.A. Vertical distance from the crest of bone to the height of the interproximal papilla between adjacent implants. *Journal of Periodontology*. 2003, 74: 1785–1788.

