

## Surgical outcome of Triple procedure PKP-ECCE-PCIOL- A case report

Shubhangi Nigwekar<sup>1</sup>, Akshay beedkar<sup>2</sup>, Aayush Tandon<sup>3</sup>, S.Misra<sup>4</sup>, S.Bangal<sup>5</sup>

### Abstract :

*Purpose: To highlight early visual rehabilitation after the triple procedure in rural hospital.*

*When corneal opacity and cataract present together triple procedure, though rare, is indicated. Prognosis for a clear graft is good in triple, as graft endothelium never touches the hard nucleus which occurs in 2 steps or sequential surgery. It provides faster visual rehabilitation. Being Single step procedure it reduces patient's hospital stay, postoperative care and follow up visits. Here we present the good surgical outcome of relatively rare one step triple procedure in respect to graft clarity on slit lamp, postoperative unaided visual acuity and the occurrence of postoperative complications in a 50 year old male patient who was practically bilaterally blind.*

**Key words:** Triple procedure, Cataract with corneal opacity, PKP-ECCE-IOL.

### Introduction

Many times the corneal opacity and cataract present together. In such cases, performing only penetrating keratoplasty (PKP) does not give good visual outcome due to underlying cataract. Prognosis for a clear graft is good in triple, as graft endothelium never touches the hard nucleus which occurs in 2 step/sequential surgery and provides faster visual rehabilitation.<sup>1,2</sup> Here we present the surgical outcome of triple procedure in a male patient who was practically bilaterally blind due to both corneal opacity and cataract, in our rural set up.

### Case report

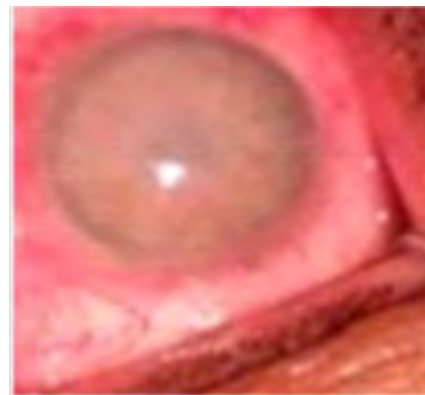**History:** 50 year old, healthy farmer presented with progressive diminished vision since 2years. He had subnormal vision in both eyes since last 40 years due to bilateral epidemic conjunctivitis.

---

<sup>1</sup>\*Professor, Senior Resident<sup>2</sup>

#### Corresponding author:

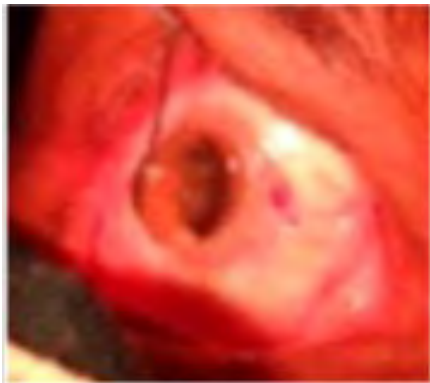Prof. Dr. Shubhangi Nigwekar  
Department of Ophthalmology, Rural Medical College of PIMS (DU),  
Loni, Maharashtra, India.  
E-mail-shubhangi2501@yahoo.in



**Fig1. Preoperative photo showing corneal haze and cataract.**

**On examination** he had counting finger 1 meter vision in both eyes. Slit lamp examination showed uniform macular grade corneal haze and nuclear cataract and brisk papillary reactions in both eyes. (Fig.1) Tonometry and lacrimal sac syringing showed normal results. B scan revealed attached retina. Patient was posted for right eye triple surgery after written consent from the patient under general anesthesia after medical fitness.

**Surgical steps** were as follows:



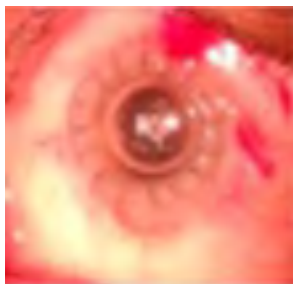**Fig.2** Intraoperative photo showing brown nucleus delivery through CCC.

Preparation of donar corneal button, removal of corneal opacity with trephine, release of iris adhesions at angle and posterior synechie, CCC, removal of nucleus with vectis and needle cystitome, (Fig. 2) implantation of PMMA rigid one piece PCIOL in bag, 2PBIs, intermittent 16- equidistant- radial 10-0 nylon sutures, AC reformation with air and saline, application of BCL, S/C antibiotic steroid injection and postoperative eye patch bandage was given for 24 hours.

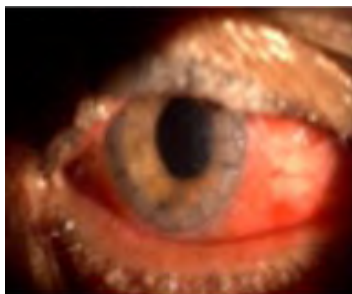
**Postoperatively** topical antibiotic steroid drops, short acting cycloplegic drops and lubricating drops were prescribed. We used systemic antibiotics and anti-inflammatory- analgesics as per need till the rural patient's hospital stay for 7 days.

**Follow up examinations** were carried out on 1<sup>st</sup> to 7<sup>th</sup> day on the indoor rural patient. (Fig. 3, 4, 5)

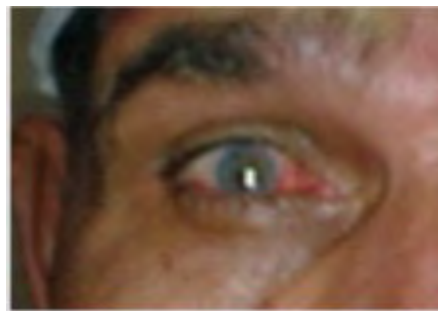During monthly follow up we recorded UCVA, ARF, and SLE & NCT- IOP.



**Fig. 3** Post operative photos showing clear graft on 1<sup>st</sup> POD



**Fig. 4** Post operative photos showing clear graft 1 week / at discharge



**Fig. 5** Post operative photos showing clear grafts after 1 year.

## Results

Patient had postoperative UCVA 6/12 far better than preoperative V/A, clear corneal graft without vascularisation, normal IOP, quiet eye with well centred PCIOL. However there was PCO after 6 months, when patient restarted working in the farm and dropped vision to 6/36. This was treated successfully with YAG capsulotomy and patient regained 6/12 vision.

## Discussion

Triple procedure which was first described by Taylor in 1976, has now become a well-established and effective surgical treatment for patients with both corneal and lenticular opacities and indicated in whom corneal surgery may accelerate cataract formation.<sup>3</sup>

Single step triple procedure, reduces the patient's hospital stay, postoperative care and follows up visits especially in elderly patients who usually have geriatric health problems.

Triple procedure gives faster visual rehabilitation and is more preferred than sequential or 2 step surgery i.e. first PKP and after suture removal ECCE with PCIOL implantation.

Performing only PKP in patients with corneal opacity in a rural senile patient reduces the patient's ultimate visual outcome as these patients loose follow up for second step IOL implantation and prefers very poor vision or no vision even with clear corneal graft.

In early periods there was a challenge of IOL power calculation for triple procedure due to corneal scars however now it is answered by use of standard constant keratometry value of 44 D and fellow eye keratometry is also an option.<sup>4,5</sup>

In two step or sequential surgeries we get more accurate IOL power after removal of sutures of PKP. However early removal of sutures in elderly patients lead weak unhealed grafts which may lead slippage of transplants. Even a minor trauma may lead globe rupture up to 5 years postoperatively. Actually PKP hastens cataract formation, particularly in eyes with moderate preexisting cataracts due to surgical trauma and inflammation as well as the postoperative topical steroid therapy. In sequential or two step surgery there may be endothelial cell loss from the precious survived clear corneal graft during cataract surgery and with borderline endothelial cell count, corneal decompensation can occur. Thus simultaneous or one step triple surgery may remain a justified option for good visual outcome in such patients.<sup>6</sup>

Clear corneal graft after the triple procedure has been found to range from 60% to 100% in the literature.<sup>7</sup>

Indications for corneal transplantation have a significant effect on graft survival so selection of the patient decides the success of surgery. Epithelial defects, secondary glaucoma, corneal vascularization, decentration of PCIOL and graft failure are known complications of triple procedure.<sup>8</sup>

Better visual acuity, controlled IOP and clear grafts without oedema in triple procedure were seen more with capsulorrhexis than can opener capsulotomy. Postoperative UCVA > 6/9 after the triple procedure has been found to range from 38% to 64% of eyes.<sup>9,10</sup>

Success in our case may be due to patients selection, minimal surgical intervention, use of good donor cornea, viscoelastic material, CCC and good IOL placement in bag, proper estimation of IOL power, 2PBIs, indoor patients for 7 days and regular follow ups with slit lamp examination which allowed proper and timely postoperative intervention like YAG capsulotomy .

## Conclusion

Triple procedure gives immediate good results in respect to graft clarity, unaided vision, and faster visual and social rehabilitation.

## References

1. Busin M, Arffa RC, McDonald MB, Kaufman HE. Combined penetrating keratoplasty, extracapsular cataract extraction, and posterior chamber

intraocular lens implantation. *Ophthalmic Surg.* 1987;18:272-5

2. Triple procedure shows promise for patients with corneal opacity and cataract. *J. Cataract Refract Surg.* 2011; 37:122-126.
3. Pineros OE, Cohen EJ, Rapuano CJ, Laibson PR. Triple vs nonsimultaneous procedures in Fuchs' dystrophy and cataract. *Arch Ophthalmol.* 1996; 114:525–528. Shimmura S, Ohashi Y, Shiroma H, Shimazaki J, Tsubota K. Corneal opacity and cataract: triple procedure versus Secondary approach. *Cornea.* 2003; 22:234–238.
4. Flowers CW, McLeod SD, McDonnell PJ, Irvine JA, Smith RE. Evaluation of intraocular lens power calculation formulas in the triple procedure. *J Cataract Refract Surg.* 1996; 22:116–122.
5. Davis EA, Azar DT, Jakobs FM, Stark WJ. Refractive and keratometric results after the triple procedure: experience with early and late suture removal. *Ophthalmology.* 1998; 105:624–630.
6. Mader TH, Yuan R, Lynn MJ, Stulting RD, Wilson A, Waring GO. Changes in keratometric astigmatism after suture removal >1yr after penetrating keratoplasty. *Ophthalmology.* 1993; 100: 119–126.
7. Factors influencing visual outcome after penetrating keratoplasty combined with intraocular lens implantation. *Eur J Ophthalmol.* 2003; 13:134-8.
8. Meyer RF, Musch DC. Assessment of success and complications of triple procedure surgery. *Am J Ophthalmol.* 1987; 104:233–240.
9. Claoué C, Ficker L, Kirkness C, and Steele A. Refractive results after corneal triple procedures (PK+ECCE+IOL). *Eye (Lond)* 1993; 7:446–451.
10. Nigwekar S et al. Surgical outcome of triple surgery as PKP with PCIOL implant in patients with both corneal opacity and advanced cataract at rural set up . *Int,J Med Res Health Sci* 2015;4(4) : 803 - 806.