

## Kocher DebreSemelaigne Syndrome: A Rare Case Report

Abhishek Gupta\*, Dhananjay Y. Shrikhande\*\*, Rajat Patel\*, AbhijeetShinde\*, Abhijit Singh\*

**Abstract :** *Kocher DebreSemelaigne syndrome is a rare condition of muscular pseudo hypertrophy and long standing moderate to severe hypothyroidism in children . A 4 year old female child from middle socio- economic status presented with complaints of short stature and hoarseness of voice since early infancy. Child had a poor appetite but no history of any weight loss or fever. Further history revealed of her being the first issue of a non-consanguineous marriage with full term normal vaginal delivery and uneventful antenatal, natal and postnatal periods. There was no history any similar complaints in the family. Her developmental milestones were expected as per the age and she had started walking by the age of 14 months. There was no history of Lethargy, poor activity, constipation or hyper- somnolence. Contrary to the usual presentation of hypothyroidism, the child was fairly intelligent and playful. To conclude , Kocher –Debre-Semelaigne syndrome is a specific, rare form of hypothyroid myopathy, which causes hypertrophy of muscles which is easily treatable with thyroid replacement therapy.*

**Keywords :** *hypothyroidism, myopathy*

### Background:

Kocher DebreSemelaigne syndrome is a rare condition of muscular pseudo hypertrophy and long standing moderate to severe hypothyroidism in children .

It was first noted by Kocher in 1892, but the relationship of the muscle pseudohypertrophy and hypothyroidism was emphasised by Debre and Semelaigne in 1935.

Clinically, this condition may masquerade as a primary muscle disorder and hence the thyroid supplementation be delayed.

The pathogenesis of the pseudohypertrophy in the disease is not completely clear. The lack of thyroid hormone impairs many metabolic functions of the body including musculoskeletal system. Impaired carbohydrate metabolism leads to glycogen accumulation in muscles;

while increased amounts of connective tissue and mucopolysaccharide deposits in the muscles also give the appearance of hypertrophy of muscles.

The overall reported incidence of KDSS is less than 10%. Severity of myopathy generally correlates with the duration and the degree of thyroid hormone deficiency. It most commonly occurs in males, and has been reported in children as the products of consanguineous marriage.

### Case report:

A 4 year old female child from middle socio- economic status presented with complaints of short stature and hoarseness of voice since early infancy. Child had a poor appetite but no history of any weight loss or fever. Further history revealed of her being the first issue of a non-consanguineous marriage with full term normal vaginal delivery and uneventful antenatal, natal and postnatal periods. There was no history any similar complaints in the family. Her developmental milestones were expected as per the age and she had started walking by the age of 14 months. There was no history of Lethargy, poor activity, constipation or hyper- somnolence. Contrary to the usual

---

\* Resident, \*\* Professor and HOD

### Corresponding author :

Dr. Abhishek Gupta  
Dept of Paediatrics, Rural Medical College,  
PIMS(DU) LONI, Dist. A'nagar (MS)

presentation of hypothyroidism, the child was fairly intelligent and playful.

Clinically, the child had short stature

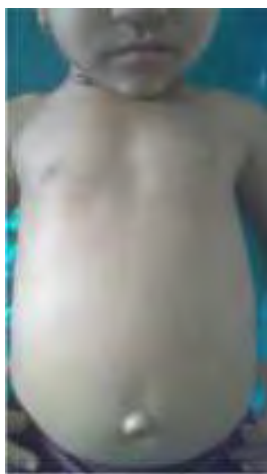
[Height – 79cm(expected 100cm i.e. <3<sup>rd</sup> percentile), US : LS ratio – 1:1.3, Arm span 75cm. *Weight* – 10.29 Kg(expected 15.9 Kg i.e. <3<sup>rd</sup> percentile)]

whereas her weight for height was greater than 50<sup>th</sup> percentile.

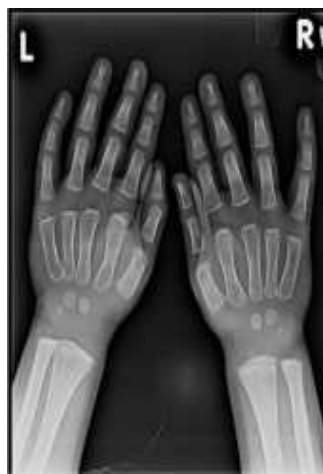Also, she had coarse and dry skin, umbilical hernia, hoarse voice and calf – thigh – gluteal muscle hypertrophy. All the muscles showed firm enlargement with the muscle tone being normal and no weakness (muscle power being 5/5) and deep tendon reflexes were normal. Gower's sign was negative. In presence of features of hypothyroidism, the pseudo hypertrophy of muscles suggested a diagnosis of Kocher-Debre-Semelaigne syndrome.



**Image : Calf and Thigh Muscle Hypertrophy**



**Image : Umbilical hernia**



**Image : X-ray wrist joint for bone age**

Thyroid profile reports revealed of Serum T4 0.634 µg/dL (n = 5.53-11.4µg/dL), serum T3 was 0.525ng/mL (n = 0.970- 1.69 ng/mL), serum TSH 100.0 µIU/mL (n = 0.465-4.68µIU/mL) and hence the diagnosis was confirmed.

## Discussion

Thyroid hormone deficiency, a cause of 5% cases of acquired myopathies, is a treatable disorder. The usual age of presentation is between 18 months and 10 years.[1-3]. There are several mechanisms whereby thyroid hormone deficiency may interfere with the normal structure and function of skeletal muscles leading to myopathy. The lack of thyroid hormone results in slowed or reduced metabolic function such as decreased protein turnover and impaired carbohydrate metabolism. These metabolic changes occur in many organ systems, including muscles. Glycogen accumulation and decreased activity of enzymes involved in energy production have been described in hypothyroid myopathy. Thyroid hormone is also necessary for the expression of fast myofibrillar proteins in muscles. In hypothyroidism, where the expression of these proteins is deficient there is an increased accumulation of slow myofibrillar proteins. Hypertrophy of muscle occurs due to increased amounts of connective tissue and mucopolysaccharide deposits.[4-6] All these factors may contribute to muscle weakness, showed muscle contraction, and diminished deep tendon reflexes, fatigue and exertional pain. Myopathy is a known complication of hypothyroidism with an incidence of musculoskeletal symptoms varying from 30-80% in different series. Although muscular symptoms may occur in many patients with hypothyroidism, muscular hypertrophy is reported in less than 10% of the patients.[5-7] The muscular hypertrophy (gastrocnemius, quadriceps) and muscles weakness were observed on physical examination in our patients. Both our patients showed an elevation in creatine kinase. The elevation of serum creatine kinase was reported in 80% of the hypothyroidism even with the absence of muscle involvement.[8] The mechanism of the release of these enzymes is attributed to the changes in cell membrane permeability.[9] Electromyogram is usually normal or may show myopathic MUAPs with reduced duration and amplitude.[10] This myopathy is responsive to replacement therapy. But if the symptoms go undiagnosed for a long

time, it may lead to short stature and intellectual delay which may not respond completely to thyroid replacement. Both our patients were diagnosed at a late age in spite of all clinical features of hypothyroidism. Rare cases have been reported in the past with Kocher-Debre-Semelaigne syndrome. Usual age of presentation is between 18 months and 10 years, but the reports of the condition being diagnosed in neonatal age are also available.[11] A rare case report of KDS presenting with pericardial effusion has also been described.[12] To conclude, Kocher-Debre-Semelaigne syndrome is a specific, rare form of hypothyroid myopathy, which causes hypertrophy of muscles which is easily treatable with thyroid replacement therapy.

### Take Home message

1. Hypothyroidism may present with musculoskeletal symptoms and myopathy.
2. If picked up early, one can limit the loss of IQ points and improve the height and reverse the height gained.

### References :

1. Virmani A, Gambhir A, Iyer PU. Kocher DebreSemelaigne syndrome mimicking primary muscle disease. *Indian Pediatr* 1990;27:88-89.
2. Luiz N. Kocher DebreSemelaigne syndrome. *Indian Pediatr* 1998;35: 1115-1116.
3. Khatua SP, Gangwal A, Khatua S. Kocher DebreSemelaigne syndrome. *Indian Pediatr* 1984;21:337-339.
4. Thasko V, Davachi F, Baboci R, Drishti G, Hoxha P: Kocher-DebreSemelaigne syndrome. *Clinical Pediatr*. 1999; 38:113-115.
5. Siciliano G, Monzani F, Manca ML, Tessa A, Caraccio N, Tozzi G et al: Human mitochondrial transcription factor A reduction and mitochondrial dysfunction in Hashimoto's hypothyroid myopathy. *Mol Med* 8: 326-333, 2002.
6. Siciloano G, Manca L, Murri L, Ferrannini E. Clinical and biochemical features of muscle dysfunction in subclinical hypothyroidism. *J Clin Endocrinol Metab*. 1997; 82: 3315-3318.
7. Ghilardi G, Gonvers JJ, So A: Hypothyroid myopathy as a complication of interferon alpha therapy for chronic hepatitis C virus infection. *Br J Rheumatol*. 1998; 37:1349-1351.
8. Mehrotra P, Chandra M, Mitra MK: Kocher Debre Semelaigne syndrome: regression of pseudohypertrophy of muscles on thyroxine. *Arch Dis Child*. 86: 224, 2002.
9. Scott Kr, Simmons Z, Boyer P. Hypothyroid myopathy with a strikingly elevated serum creatine kinase levels. *Muscle and Nerve* 2002;26:141-144.
10. Ruurd FD, Bosch J, Laman DM: Neuromuscular findings in thyroid dysfunction a prospective clinical and electrodiagnostic study. *J Neurology Neurosurg Psychiatry*. 2000;68:750-755.
11. Tullu MS, Udgiakar VS, Muranjan MN, Sathe SA, Kamat JR. Kocher Debre Semelaigne syndrome: hypothyroidism with muscle pseudohypertrophy. *Indian J paediatrics* 2003;70:671-3.
12. Praveen dharaskar, milind S tullu, keya R lahiri, santosh kondekar, rajwanti k. vaswani. Kocher Debre Semelaigne syndrome with pericardial effusion. *Indian J Med sci*, vol. 61, sept 2007;527-530.

